

University of Louisville

## ThinkIR: The University of Louisville's Institutional Repository

---

Electronic Theses and Dissertations

---

5-2010

# In vitro detection of mesio-buccal canals in maxillary molar cross-sections using three different resolutions with Kodak 9000 3D CBCT.

Jolanta Nowicka Sauer  
*University of Louisville*

Follow this and additional works at: <https://ir.library.louisville.edu/etd>

---

### Recommended Citation

Sauer, Jolanta Nowicka, "In vitro detection of mesio-buccal canals in maxillary molar cross-sections using three different resolutions with Kodak 9000 3D CBCT." (2010). *Electronic Theses and Dissertations*. Paper 1267.  
<https://doi.org/10.18297/etd/1267>

This Master's Thesis is brought to you for free and open access by ThinkIR: The University of Louisville's Institutional Repository. It has been accepted for inclusion in Electronic Theses and Dissertations by an authorized administrator of ThinkIR: The University of Louisville's Institutional Repository. This title appears here courtesy of the author, who has retained all other copyrights. For more information, please contact [thinkir@louisville.edu](mailto:thinkir@louisville.edu).

***IN VITRO* DETECTION OF MESIO-BUCCAL  
CANALS IN MAXILLARY MOLAR CROSS-  
SECTIONS USING THREE DIFFERENT  
RESOLUTIONS WITH KODAK 9000 3D CBCT**

By  
Jolanta Nowicka Sauer  
Masters Candidate in Oral Biology at the  
University of Louisville School of Dentistry

A Thesis  
Submitted to the Faculty of the  
Graduate School of the University of Louisville  
In Partial Fulfillment of the Requirements  
For the Degree of

Master of Science

Program in Oral Biology  
School of Dentistry  
University of Louisville  
Louisville, Kentucky

May 2010

Copyright © 2010 by Jolanta Nowicka Sauer  
All rights reserved

***In Vitro* detection of mesio-buccal canals in maxillary  
molar cross-sections using three different resolutions  
with Kodak 9000 3D CBCT**

By  
Jolanta Nowicka Sauer  
Masters Candidate in Oral Biology at the  
University of Louisville School of Dentistry

**A Thesis Approved on**

April 09, 2010

**By the following Thesis Committee:**

---

Allan ~~G.~~ Farman, BDS, PhD, DSc  
Thesis Director

---

William C. Scarfe, ~~BDS~~, FRACDS, MS  
~~Co~~-Thesis Director

---

~~S~~Stephen J. Clark, DMD  
Committee member



## DEDICATION

I would like to dedicate this thesis to my wonderful parents – Maria and Antoni Nowicki of Olesnica, Poland for their example of educational dedication, continuous love, and emotional support throughout the years. Their support and encouragement motivated me to set goals and accomplish the necessary tasks at hand.

I am also grateful to my dear husband, Jeff Sauer, for his love, patience, and support. Without his support and constant encouragement it would not have been possible for me to reach my full potential.

Pragne zadedykowac ta prace naukowa dla moich wspanialych Rodzicow – Maria i Antoni Nowicki z Olesnicy, Polski za ich przyklad poswiecenia sie dla edukacji. Pragne zadedykowac moja prace dla nich za nieustajaca milosc jaka mnie zawsze obdarzali i emocjonalne wsparcie przez wszystkie lata mojego zycia na ktore zawsze moglam liczyc. Zdaje sobie sprawe z tego, ze bez ich pomocy, motywacji i nieustajacej wiary we mnie nie moglabym wiele osiagnac w zyciu.

## **ACKNOWLEDGEMENTS**

I am greatly indebted to the following for their assistance on this project:

To Dr. Allan G. Farman, thesis director and mentor, for his continuous guidance and support throughout the years. The opportunity to work with Dr. Farman and learn from an accomplished, renowned investigator and clinician has been a privilege and honor. I thank him for accepting me as a research student, having always faith in me and guiding me through out the many years at school to the completion of a successful research study. He sacrificed numerous hours of his personal time to educate and mentor me on this research project and many other courses and projects. I have learned a wealth of knowledge and wisdom from him. Dr. Farman above and beyond his duty as a mentor in the support he provided me at the ULSD. I thank him for all of his direction, and his friendship. I appreciate his patience and assistance in the writing and editing of the final manuscript. Without his assistance this thesis would not have been accomplished.

To Dr. William C. Scarfe, co-thesis director for guidance in this study. It was a privilege to work on this project with him. Dr. Scarfe always found time for me whenever I needed his help. He took a personal interest in my work and other academic endeavors and provided me with exceptional guidance and support. Even when he was busy with other projects, he would take the time to help me. On numerous occasions he helped me

with editing my work. I have learned a great deal through his guidance. I would like to thank him for his friendship and all of the contributions he has made to this study.

To Mrs. Barbara Mercer, Mrs. Elaine Luckett, Mrs. Lisa Wade and Mrs. Lucinda Perry, radiologic technologists, for their support and the accommodations made for me in the Radiology and Imaging Sciences.

To Dr. Stephen J. Clark, the director of the endodontic program. Without him, it would not have been possible for me to reach my full potential in my studies. Dr. Clark inspired me every day by his professionalism and dedication to research. He has helped guide each step of my academic journey. He has taken time to review various ideas and potential methods to examine those ideas. I thank him for his patients when he had to explain various principles related to statistics. I thank him for always accommodating the time and effort for this project to be successful.

To Dr. Lawrence Gettleman for the use of his laboratory to section the mesio-buccal roots for analysis.

To my co-endodontic residents, Drs: Gregory Carman, Kirk Brown, Shea Chevront, Brad Christensen and Chris Olson and Drs. Joseph Morelli and Ricardo Caicedo who took the time to watch a lengthy presentation consisting of 123 videos, evaluate the cross-sections, and report their findings for my research.

To Joyce Wiedmar, clinical assistant and Kim Shealy, office manager for accommodations made in endodontic clinic and their support and continuous encouragement.

To Jennifer Baker, secretary to Dr. Clark, for her assistance with complying with the many details and deadlines involved with this paper.

To David Ludwig for helping to fix “computer” difficulties and editing this manuscript.

To Dr. Doug Chenin for explaining the principles and applications of Dental Software, *In VivoDental* (Anatomage, San Jose, CA, USA).

Lastly to Dr. Scheetz and his wife Mikki, who helped me to analyze the data during his personal, free time. Without his help this study could not be finished on time.

## ABSTRACT

# ***IN VITRO* DETECTION OF MESIO-BUCCAL CANALS IN MAXILLARY MOLAR CROSS- SECTIONS USING THREE DIFFERENT RESOLUTIONS WITH KODAK 9000 3D CBCT**

Jolanta Nowicka Sauer

April 9, 2010

CBCT in endodontics demonstrates anatomic features in 3D that intraoral, panoramic, and cephalometric images cannot. CBCT units reconstruct the projection data to provide interrelational images in three orthogonal planes (axial, sagittal, and coronal). In addition because reconstruction of CBCT data is performed natively using a personal computer, data can be reoriented in their true spatial relationships.

**Aims:** To investigate accurate detection of the correct number of root canals in the mesio-buccal root of the maxillary molar teeth using 3D imaging with cone beam computed tomography (CBCT) at different spatial resolution (isotropic voxel) settings.

**Methods:** With IRB approval, 31 extracted maxillary molars were examined using high resolution, small field of view CBCT at isotropic voxel resolutions ranging at 0.076, 0.10 and 0.20 mm. The image data sets were imported into third party segmentation software to provide 3D videos for 8 observers to determine the number of mesio-buccal root canals

in cross-sectional reconstructions. The ground truth was later established by sectioning the tooth roots axially.

**Results:** Twenty-four of the teeth proved on sectioning to have two mesio-buccal canals whereas the others had one canal. Accuracy in detection of mesio-buccal canals varied between observers from 59% to 75% and statistically unrelated to observer experience. No statistical differences were found between the reconstructed 3D images regarding accurate detection of canals.

**Conclusions:** CBCT outperformed the findings for accuracy in detection of mesio-buccal root canals in all previous studies using 2D imaging modalities and Tuned Aperture Computed Tomography.

**Keywords:** Computed Tomography, X-ray, Cone-Beam; Endodontics; Image processing

## TABLE OF CONTENTS

	<b>PAGE</b>
THESIS APPROVAL/SIGNATURE PAGE.....	ii
DEDICATION.....	iii
ACKNOWLEDGEMENTS.....	iv
ABSTRACT.....	vii
LIST OF FIGURES .....	xi
LIST OF TABLES.....	xvi
 <b>CHAPTER</b>	
<b>I. INTRODUCTION AND LITURATURE REVIEW.....</b>	<b>1</b>
1. Historical Background .....	2
2. Prelude to CBCT scanners.....	6
3. Cone Beam Computed Tomography .....	10
4. Currently Available CBCT .....	12
5. Radiology and CBCT in Endodontics.....	18
6. Mesio-Buccal Root in Maxillary Molars .....	20
<b>II. STATEMENT OF OBJECTIVES AND HYPOTHESIS .....</b>	<b>26</b>
1. Study Objectives .....	26
2. Study Hypothesis .....	27
<b>III. METHODS AND MATERIALS.....</b>	<b>29</b>
1. Overview.....	29
2. Sample.....	29
3. Imaging procedure for CBCT 3D acquisition.....	33

4.	Image Reconstruction and Display .....	42
5.	Data Collection .....	52
6.	Video Observations.....	54
7.	Determination of Anatomic Truth .....	55
8.	Tooth Sectioning .....	55
9.	Staining of the Cross-Sections .....	58
10.	Microscopic Evaluation .....	67
11.	Data Analysis .....	84
IV.	RESULTS .....	85
1.	Ground Truth .....	85
2.	Descriptive measure of overall accuracy .....	87
3.	Rater choice compared to truth .....	88
4.	Rater accuracy related to observers experience .....	90
V.	DISCUSSION AND CONCLUSION .....	95
VI.	REFERENCES .....	99
VII.	APPENDIX.....	104
1.	Appendix A .....	104
2.	Appendix B .....	105
3.	Appendix C .....	106
4.	Appendix D.....	109
5.	Appendix E .....	110
VIII.	CURRICULUM VITAE.....	114



## LIST OF FIGURES

<b>FIGURE</b>	<b>PAGE</b>
1. Rektor Wilhelm Konrad Röntgen .....	4
2. Johann Radon .....	5
3. Godfrey N. Hounsfield .....	7
4. Allan MacLeod Cormack .....	8
5. Newtom 9000G .....	12
6. CB MercuRay .....	12
7. 3D Accuitomo .....	13
8. i-CAT Conebeam CT .....	13
9. Kodak 9000 3D .....	14
10. Nine Experimental Models with Three Teeth.....	30
11. Two Experimental Models with Two Teeth .....	31
12. Numbered crowns with a black sharpie marker (1-31) for identification.....	32
13. Screenshot of acquisition computer turned on.....	33
14. Selection of KODAK Dental Imaging Software .....	34
15. Screen shot of initial start up screen of KODAK Dental Imaging Software .....	34
16. Placement of experimental models on the support prior to acquisition.....	36
17. Arrangement of a plastic container with experimental model immersed in water	36
18. Demonstration of the vertical and horizontal laser lights .....	37
19. Demonstration of the vertical and mid-saggital laser lights .....	38

20.	Initial interface of the KODAK Dental Imaging Software .....	39
21.	Parameters used under “Patient” selection .....	40
22.	Voxel resolution 0.076 mm.....	40
23.	Voxel resolution 0.1 mm.....	41
24.	Voxel resolution 0.2 mm.....	41
25.	Image on KODAK Dental Image Software .....	42
26.	Screenshot of dataset using KODAK Dental Imaging Software in orthogonal display mode .....	43
27.	KODAK Dental Imaging Software cross sections of experimental models oriented such that palatal roots are oriented to the top of the screen .....	44
28.	Screenshot of opening InVivoDental (Anatamage) software .....	45
29.	Reorientation of the experimental models on the screen .....	46
30.	Reorientation of the experimental models on the screen .....	46
31.	Reorientation of the experimental models on the screen in Vivo Software .....	47
32.	InVivoDental Video software Icon .....	48
33.	Icon used to separate teeth so there will be on the screen .....	49
34.	Drawing around each tooth to separate them.....	49
35.	Single tooth on the screen .....	50
36.	Cross section of tooth.....	50
37.	“Customized” settings.....	51
38.	Video Capture .....	52
39.	Random Sequence Generator.....	53
40.	Random sequence of numbers generated to determine the repeat 10 videos from each folder of three different resolutions .....	53

41.	Observers'assessment form .....	55
42.	Marked 2 mm horizontal cross-sections .....	56
43.	Making 2 mm horizontal sections of mesio-buccal root of molar .....	57
44.	2 mm horizontal sections of mesio-buccal root of molar .....	57
45.	Teeth with their 2 mm cross-sections .....	58
46.	Root canal locator dye .....	59
47.	Photographic view of cross-sections teeth 1 & 2.....	59
48.	Photographic view of cross-sections teeth 3 & 4.....	60
49.	Photographic view of cross-sections teeth 5 & 6.....	60
50.	Photographic view of cross-sections teeth 7 & 8.....	61
51.	Photographic view of cross-sections teeth 9 & 10.....	61
52.	Photographic view of cross-sections teeth 11 & 12.....	62
53.	Photographic view of cross-sections teeth 13 & 14.....	62
54.	Photographic view of cross-sections teeth 15 & 16.....	63
55.	Photographic view of cross-sections teeth 17 & 18.....	63
56.	Photographic view of cross-sections teeth 19 & 20.....	64
57.	Photographic view of cross-sections teeth 21 & 22 & 23.....	64
58.	Photographic view of cross-sections teeth 24 & 25.....	65
59.	Photographic view of cross-sections teeth 26 & 27.....	65
60.	Photographic view of cross-sections teeth 28 & 29.....	66
61.	Photographic view of cross-sections teeth 30 & 31.....	66
62.	Cross-sections under microscope.....	67
63.	Microscope and camera set up.....	68

64.	Microscopic view of tooth #1 .....	68
65.	Microscopic view of tooth #2 .....	69
66.	Microscopic view of tooth #3 .....	69
67.	Microscopic view of tooth #4 .....	70
68.	Microscopic view of tooth #5 .....	70
69.	Microscopic view of tooth #6 .....	71
70.	Microscopic view of tooth #7 .....	71
71.	Microscopic view of tooth #8 .....	72
72.	Microscopic view of tooth #9 .....	72
73.	Microscopic view of tooth #10 .....	73
74.	Microscopic view of tooth #11 .....	73
75.	Microscopic view of tooth #12 .....	74
76.	Microscopic view of tooth #13 .....	74
77.	Microscopic view of tooth #14 .....	75
78.	Microscopic view of tooth #15 .....	75
79.	Microscopic view of tooth #16 .....	76
80.	Microscopic view of tooth #17 .....	76
81.	Microscopic view of tooth #18 .....	77
82.	Microscopic view of tooth #19 .....	77
83.	Microscopic view of tooth #20 .....	78
84.	Microscopic view of tooth #21 .....	78
85.	Microscopic view of tooth #22 .....	79
86.	Microscopic view of tooth #23 .....	79

87.	Microscopic view of tooth #24 .....	80
88.	Microscopic view of tooth #25 .....	80
89.	Microscopic view of tooth #26 .....	81
90.	Microscopic view of tooth #27 .....	81
91.	Microscopic view of tooth #28 .....	82
92.	Microscopic view of tooth #29 .....	82
93.	Microscopic view of tooth #30 .....	83
94.	Microscopic view of tooth #31 .....	83
95.	Rater choice compared to truth .....	88
96.	Rater choice compared to truth in both original and repeat videos .....	89
97.	Overall accuracy compared to the ground truth.....	91
98.	Percent accuracy of MB2 detection .....	93

## LIST OF TABLES

<b>TABLE</b>		<b>PAGE</b>
1.	Current commercially available CBCT equipment.....	15
2.	Ground truth .....	85
3.	Rater accuracy with observers experience .....	90

# CHAPTER I

## INTRODUCTION AND LITERATURE REVIEW

Most current imaging techniques in the dental office are 2-dimensional representations of 3-dimensional (3D) objects (1-4). However, cone-beam computed tomography (CBCT) has gained considerable acclaim worldwide in recent years as a viable 3D imaging modality. To date most applications of CBCT have been in fields of implantology, oral and maxillofacial surgery, oral and maxillofacial radiology, and orthodontics (5).

Improved spatial resolutions and more user-friendly software programs have opened the door for more clinicians than ever before to use this technology. Endodontic applications are growing in popularity. Researchers have shown that CBCT has greater sensitivity in detecting apical periodontitis, when compared to periapical and panoramic radiographs (6). In a population of 888 consecutive patients (1508 teeth) with endodontic infection, the prevalence of apical periodontitis, when comparing panoramic and periapical radiographs and CBCT, was 17.6%, 35.3%, and 63.3%, respectively ( $P < .001$ ) (6). With such a strong impact already suggested in the literature, this research project describes CBCT and its practicality as a diagnostic tool in clinical endodontic practice.

RCT (Root Canal Therapy) is the procedure to cure the infection and save the tooth where dentist drills into the pulp chamber and removes the infected pulp by scraping it out of the root canals. Once this is done, the dentist fills the cavity with an inert material and seals up the opening. The long term success of the endodontic therapy depends greatly on the clinician's ability to locate and identify all canals present.

## **1. Historical Background**

X-rays are electromagnetic waves, like light waves, but with a wavelength about 1,000 times smaller. Because of this very short wavelength, X-rays can easily penetrate low-density material, such as flesh. They are reflected or absorbed, however, by high-density material such as bone. The image made by radiography shows the denser materials (like bones) as light areas (i.e. the radiograph is a negative). The X-ray was discovered by physicist Wilhelm Conrad Röntgen (Fig.1) on November 8, 1895. He was studying the phenomena accompanying the passage of an electric current through a gas of extremely low pressure. On the evening of November 8, he found that if a paper plate covered on one side with barium platinocyanide was placed in the path of the rays it became fluorescent even when it was as far as two meters from the discharge tube. Röntgen showed that the new rays are produced by the impact of cathode rays on a material object. Because their nature was then unknown, he gave them the name X-rays (7). Röntgen delivered a paper detailing his findings on December 28, 1895. In the paper he admitted that he did not know the precise nature of these new rays. He chose to name



them “X-rays”, since “X” is the mathematical symbol for the unknown. Within a few months of the discovery, Reiniger, Gebbert and Schall began the first commercial production of an x-ray apparatus in Germany. The first dental radiograph is attributed to Friedrich Otto Walkoff of Braunschweig, Germany, who made images of the crowns of teeth using silver halide emulsion on glass plates in 1896. The first “film” image exposure time was 25 minutes (8). Reiniger, Gebbert and Schall introduced the 'Record' as the first dental x-ray unit in 1905 (9). Since Röntgen’s discovery of X-rays the dental film has been the standard for radiography in dentistry. William G. Stuber with Eastman Kodak developed the silver halide X-ray film specifically for dentistry (8). Although radiographs revolutionized medicine and dentistry they were still 2D images of 3D objects, therefore 3D modalities began to be explored in 1917. An Austrian mathematician Johann Radon (Fig.2) proved that an image of a three-dimensional object could be produced from its mathematical projections (10).



**FIGURE 1**

Rektor Wilhelm Konrad Röntgen (1815-1923)

Discoverer of X-rays

(Source: [http://nobelprize.org/nobel\\_prizes/physics/laureates/1901/rontgen-bio.html](http://nobelprize.org/nobel_prizes/physics/laureates/1901/rontgen-bio.html))



**FIGURE 2**

Johann Radon

Mathematician who proved that an image of a three-dimensional object could be produced from its mathematical projections

(Source: [http://en.wikipedia.org/wiki/Johann\\_Radon](http://en.wikipedia.org/wiki/Johann_Radon))

## **2. Prelude to CBCT Scanners**

In 1972, Hounsfield (Fig.3) revolutionized diagnostic medicine with the introduction of the Computed Tomography (CT) scanner by the British firm EMI Ltd based on the developments of the British engineer, Godfrey Hounsfield. Together with A.M. Cormack (Fig.4), a South African physicist at the Groote Schuur Hospital in Cape Town who contributed to the development of CT in the 50s and 60s, Hounsfield was awarded the Nobel Prize for Medicine in 1979 (11-12).

From this work conventional or fan beam CT scanners were developed. They are mostly designed for full body scanning and acquire data in the axial plane by scanning a patient with a narrow fan shaped X-ray beam obtaining the image slice by slice. The slices are then stacked together to create the three dimensional image. One of the major limitations of medical CT machines is that they are large and very expensive systems (13).



**FIGURE 3**

Godfrey N. Hounsfield  
Inventor of  
computed tomography in 1970-1971  
(Source: <http://media-2.web.britannica.com/eb-media/57/21057-004-11E821AF.jpg>)



**FIGURE 4**

Allan MacLeod Cormack (1924-1998)

Inventor of  
computed tomography in 1970-1971

(Source: <http://www.britannica.com/EBchecked/topic/137722/Allan-MacLeod-Cormack>)

CBCT uses a beam geometry providing multiple transmission images that are integrated directly forming volumetric information (14). One of the earliest 3D volumetric scanners was the Dynamic Spatial Reconstructor (DSR), conceived as early as 1975 and finally installed in the Medical Sciences Building on the Mayo Clinic Rochester campus in 1978 (15). Fourteen rotating 2D cameras with 240 scan lines each receive photons of 14



opposing X-ray point sources at a frequency of 1/60 seconds.

The system was very large, with a gantry measuring 4.57 meters in diameter and 6.24 meters in length. The device weighed more than 15,200 kilograms.

At the time the DSR was developed, 3D reconstruction algorithm was still not available.

In need of pioneering results, the DSR was forced to employ a standard 2D reconstruction algorithm, originally designed to reconstruct cross-sectional slices from fan-beam projection data. In an approach termed the “stack-of-fans” method, the DSR simply treated each axial row of projection data as coming from a rotating virtual 2D fan-beam source, located in the same plane. The DSR was used as a non-invasive diagnostic device to detect lung cancer and heart disease in their early stages.

Several CBCT systems have been developed specifically for angiography (16-21), radiation therapy planning (22-25), and mammography (26-27). While computed tomography (CT) was conceived in the mid 1970s, its application in dentistry was not immediate because of cost, size, and dose considerations. It is only since the late 1990's that computers capable of computational complexity and x-ray tubes capable of continuous exposure have enabled clinical systems to be manufactured that are both inexpensive and small enough to be used in the dental office.

### **3. Cone Beam Computed Tomography**

CBCT differs from fan beam CT because it uses an X-ray cone instead of a narrow fan beam to acquire the data. A three dimensional cylindrical volume of data is obtained with a single pass of the cone as opposed to multiple passes with the traditional fan. The volume of data is variable between different machines. The volume is described as the field of view (FOV).

A patent application for the first commercially successful maxillofacial CBCT was made in Italy in 1995 with Attilio Tacconi and Piero Mozzo as co-inventors and the system was designed and produced by Quantitative Radiology in Verona, Italy. The system was reported at SIRM Milano in June 1996, ECR Vienna, X March 1997 and CARS/CMI Paris June 1999 (28). Prototypes were tested by Polizzi (Verona, Italy, 1996), Novarad (Venice, Italy, March 27 1997), Bianchi (Torino, Italy, April 8, 1997), Ortega (Madrid, Spain, May 16, 1997) and Jacobs (Maerburg, Germany, September 5, 1997). Approval for sale of the first commercially available unit developed from these efforts in the United States, the NewTom DVT 9000 (Maxiscan in Italy only, branded by Esaote) by the Food and Drug Administration (FDA) was granted March 8, 2001 with the first installation being at the University of Loma Linda, CA (April 2001). The NewTom DVT 9000 was the first generation (produced from 1997-2004) followed by the NewTom 3G from 2004 onwards and the NewTom VG from 2007. All NewTom versions prior to the VG had the patient supine. The VG has the patient positioned standing vertically.

FDA approval for three more CBCT units quickly followed in 2003 followed for the J Morita Manufacturing Corporation's 3D Accu-itomo (March 6, 2003), the Imaging Sciences International i-CAT (October 2, 2003) and for the Hitachi CB MercuRay



(October 20, 2003). All three of these systems have the patient seated with the head vertical (29).

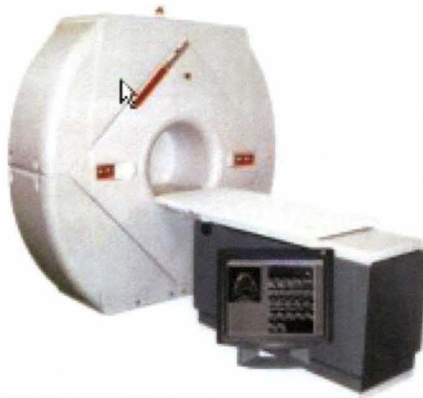The J. Morita Manufacturing Corporation (Kyoto, Japan) Accu-i-tomo initially had a 4cm FOV that has subsequently been expanded to more than twice that size. J. Morita has also released a hybrid CBCT, cephalometric and panoramic unit, the Veraviewepocs-3D at the IDS in Cologne, Germany, in 2007, and this is now FDA approved for sale in the United States (30).

The first CBCT unit manufactured in the United States was the i-CAT (Imaging Sciences International, Hatfield, PA, USA) which saw its development initiated at the Engineering School, The University of Michigan, USA and was advanced as part of the doctoral program for a bright young student, Predrag Sukovik, from Belgrade, Serbia. In prototype this system was termed the DentoCAT (14).

Hitachi engineer, Rika Baba, had a major role in helping develop the Hitachi MercuRay, and subsequently in extending the range of CBCT products for anatomical sites other than the maxillofacial region. The MercuRay is a relatively large and heavy unit that in Japan has been replaced by the smaller Hitachi CB Throne. This smaller unit appears to be distributed solely to the Japanese market at the time of writing time (30).

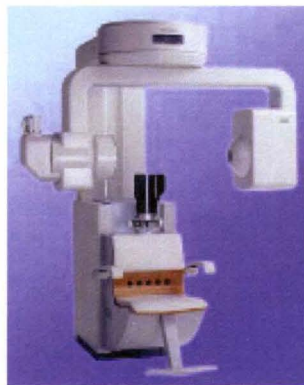
#### 4. Currently Available CBCT

Examples of current commercially available CBCT units for dento-maxillofacial radiology:



**FIGURE 5**

Newtom 9000G (Quantitative Radiology, Verona, Italy)



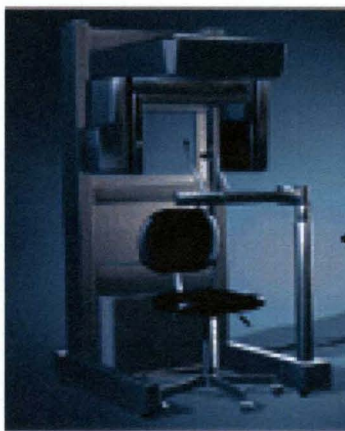
**FIGURE 6**

CB MercuRay (Hitachi, Medical Corp., Kashiwa-shi, Chiba-ken, Japan)



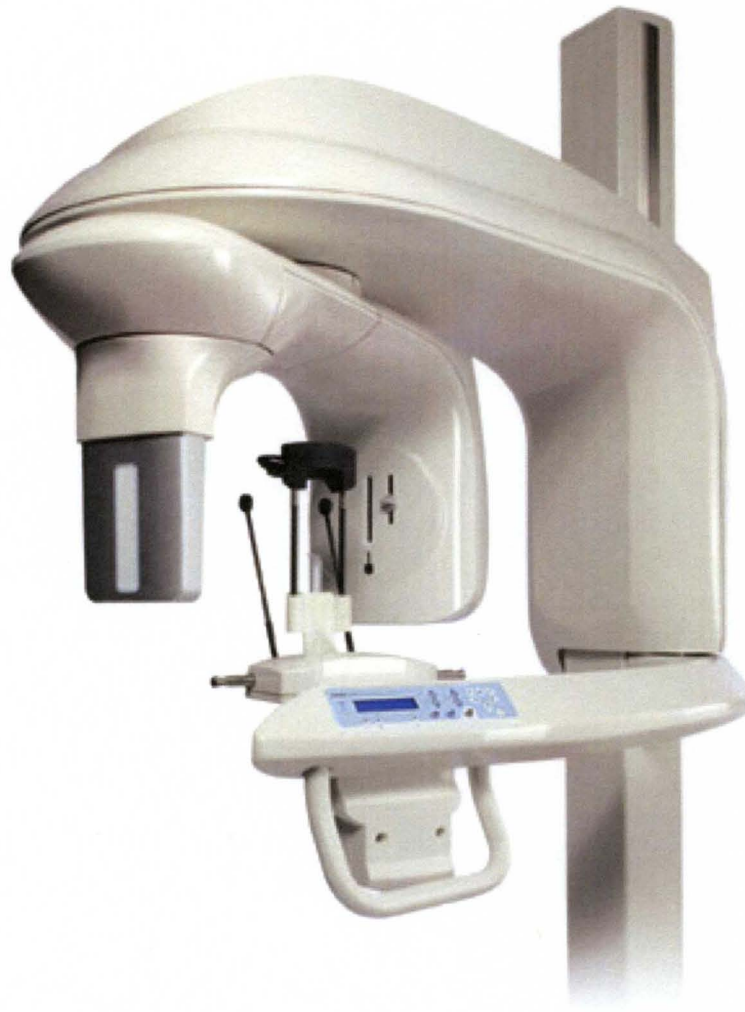**FIGURE 7**

3D Accuitomo – XYZ Slice View Tomograph, (J. Morita Mfg. Corp., Kyoto, Japan)



**FIGURE 8**

i-CAT Conebeam CT (Danaher/Imaging Sciences International, Hatfield, PA)



**FIGURE 9**

Kodak 9000 3D (Carestream, Marne-la-Vallée, France)

<i>Unit</i>	<i>Model(s)</i>	<i>Manufacturer / Distributor</i>
Accuitomo	3D Accuitomo - XYZ Slice View Tomograph / Veraviewpacs 3D	J. Morita Mfg. Corp., Kyoto, Japan
Galileos	Galileos	Sirona Dental Systems, Charlotte, NC, USA
GENDEX	CB 500	Imaging Sciences International, Hatfield, PA, USA / Distributed by Gendex, Chicago, Illinois
Hitachi	CB MercuRay / CB Throne	Hitachi Medical Corp., Chiba-ken, Japan
i-CAT	Classic/ Next Generation	Imaging Sciences International, Hatfield, PA, USA
ILUMA	Ultra Cone Beam CT Scanner	MTEC Imaging Ardmore, OK, USA
KaVo	3D eXam	Imaging Sciences International, Hatfield, PA, USA / Distributed by KaVo Dental Corp., Biberach, Germany
KODAK	9000 3D / 9500 3D	KODAK Dental Systems, Carestream Health Rochester NY, USA, distributed exclusively in the United States by PracticeWorks, Atlanta, GA
Newtom	3G / NewTom VG	QR, Inc. Verona, Italy / Dent-X Visionary Imaging, Elmsford, NY
ORION	RCB-888	Ritter Imaging GmbH, Ulm, Germany
Picasso Series	Trio / Pro / Master	E-Woo Technology Co.,Ltd, /Vatech, Giheung-gu, Korea
PreXion 3D		TeraRecon In., San Mateo, CA, USA
Promax	3D	Planmeca OY, Helsinki, Finland
Asahi Roentgen	PSR 9000N	Asahi Roentgen, Kyoto, Japan / Distributed by Belmont, Tokyo, Japan
Scanora	Scanora 3D CBCT	SOREDEX , Tuusula, Finland
SkyView	3D Panoramic imager	My-Ray Dental Imaging, Cefla Dental Group, Imola, Italy

**TABLE 1**

Current Commercially Available CBCT Equipment

How is a CBCT scan performed?

There are some universal concepts to be considered when operating CBCT units.

The patient is seated or stood in CBCT unit, similar to panoramic radiography unit, between an x-ray source and image detector. Relevant patient information is entered into software program, and the area of the head to be scanned is positioned. Upon starting the scan, there is a cone-shaped beam of x-ray radiation that is emitted from a source to the patient. The “shadow” of a patient is then cast into the detector. The source and detector together move in one 360 degree rotation around the patient. This 3D volume of a captured data is, essentially, a cylinder of pixels called “voxels”, which vary in dimensions depending on the manufacturer and scan settings selected by the operator. Basically the smaller and more numerous the voxels, the better the spatial resolution.

CBCT systems can be categorized according to the orientation of the patient during image acquisition or scan volume irradiated.

### *Patient Positioning*

CBCT can be performed with the patient in three possible positions; 1) patient sitting, 2) patient standing and, 3) patient supine. Equipment that requires the patient to lie supine physically occupies a larger surface area or physical footprint and may not be accessible for patients with physical disabilities. Standing units may not be able to be adjusted to a height to accommodate wheelchair bound patients. Seated units are the most comfortable, however fixed seats may also not allow scanning of physically disabled or wheelchair bound patients. As scan times are often greater than that used with panoramic imaging, perhaps more important than patient orientation is the head restraint mechanism used.

### *Scan Volume*

The dimensions of the field of view (FOV) or scan volume able to be covered is primarily dependent on the detector size and shape, beam projection geometry and the ability to collimate the beam. The shape of the scan volume can be either a cylinder or spherical (e.g. Newtom 3G).

Collimation of the primary x-ray beam limits x-radiation exposure to the region of interest. Field size limitation therefore ensures that an optimal FOV can be selected for each patient based on disease presentation and the region designated to be imaged. Based on available or selected scan volume height, the use of units can be designed as:

- 1) localized region - approx. 5cm or less (e.g. dento-alveolar, TMJ),
- 2) single arch - 5cm to 7cm (e.g. maxilla or mandible),
- 3) inter-arch – 7cm to 10cm (e.g. mandible and superiorly to include the inferior concha),
- 4) maxillofacial – 10cm to 15cm (e.g. mandible and extending to nasion) or
- 5) craniofacial – greater than 15cm (e.g. from the lower border of the mandible to the vertex of the head).

Extended FOV scanning incorporating the craniofacial region is difficult to incorporate into cone beam design because of the high cost of large area detectors. The expansion of scan volume height has been accomplished by one unit (i-CAT Extended Field of View model) by software addition of two rotational scans to produce a single volume with 22cm height. Another novel method to increase the width of the FOV yet using a smaller area detector, thereby reducing manufacturing costs, is to offset the position of the

detector, collimate the beam asymmetrically and scan only half the patient (e.g. Scanora 3D, SOREDEX, Tuusula, Finland)

## **5. Radiology and CBCT in Endodontics**

Radiography is essential to successful diagnosis of odontogenic and nonodontogenic pathoses, treatment of the pulp chamber and canals of the root of a compromised tooth via intracoronary access, biomechanical instrumentation, final canal obturation, and assessment of healing. Imaging serves at all stages in endodontics (31)

Preoperative Assessment. Imaging achieves visualization of dental and alveolar hard tissue morphology and pathologic alterations to assist correct diagnosis. It provides information on the morphology of the tooth including location and number of canals, pulp chamber size and degree of calcification, root structure, direction and curvature, fractures, iatrogenic defects, and the extent of dental caries. The effects of periradicular and periapical disease can be determined, including the degree of root resorption and characteristics of periapical osteolysis. Larger lesions, only determined by imaging, may necessitate adjunctive surgical procedures in addition to conventional intracanal therapy. Diagnostic radiographs help predict the potential for complications, permit root fracture detection, and demonstrate periapical lesions (32).

Intraoperative. During therapy two intraoral periapical images may be performed. The first is a “working” radiograph achieved by placement of a metallic file(s) into the root canal(s) to a length that approximates that of the root as radiological and anatomic root apices are almost never coincident. This ensures that mechanical debridement of the



intracanal contents extends to the apical terminus of the canal and that obturation is dense, homogeneous, and contained within the root canal system. In addition, prior to final obturation, a “final” or pre-condensation radiograph is made to assure proper fitting of the master cone.

Postoperative. A “postoperative” radiograph immediately after root canal obturation is made to assess the sealing condensation and containment of the root canal filling material within the root canal system. In cases where periradicular healing is incomplete, it acts as a baseline for assessment of healing in the medium and potentially long term. Imaging is important in evaluating the results of previous therapy, delayed healing, evaluating potential obstacles to retreatment, as well as surgical considerations (33).

Perhaps the most important advantage of CBCT in endodontics is that it demonstrates anatomic features in 3D that intraoral, panoramic, and cephalometric images cannot. CBCT units reconstruct the projection data to provide interrelational images in three orthogonal planes (axial, sagittal, and coronal). In addition because reconstruction of CBCT data is performed natively using a personal computer, data can be reoriented in their true spatial relationships (32).

## **6. Mesio-Buccal Root of Maxillary Molars**

In 1960 Healey, *et al.* stated that the ultimate objective of endodontic therapy is the obliteration of the prepared root canal space with inert material in order to restore integrity and state of good health of the treated tooth in dental arch (34). Ingle (35), in 1964 described the most common cause of endodontic failure being apical percolation, with the largest percentage of cases failing due to incomplete canal obliteration. Other reasons for failure in this category include leaving a canal completely unfilled and inadvertently removing a silver point. Quite often a canal is left unfilled because the operator has failed to recognize its presence. Therefore, it is the obligation of those interested in endodontics to be thoroughly familiar with root canal anatomy, in both normal and abnormal situations, in order to keep this cause of endodontic failure to a minimum.

In 1969 Weine, *et al.* (36) performed study on the mesio-buccal roots of 208 extracted maxillary first molars in order to come up with canal configurations. Teeth in the study were sectioned from a mesial approach in a buccolingual direction with a disk. The canal configurations fell into three categories:

Type I. A single canal from the pulp chamber to the apex. (48.5 %)

Type II. A larger buccal canal and a smaller canal located lingual to the former which merges from 1 to 4 mm from the apex. (37.5%)

Type III. Two distinct canals and two distinct apical foramina, with the buccal canal being larger and usually longer from the roof of the chamber to its apical foramen. (14%)

Since it is extremely difficult to determine which canal configuration is present, it is suggested (36) that whenever the mesio-buccal canal of the maxillary first molar is resected, the endodontist assume that a Type II or III is present and the long buccolingual preparation and apical filling should be employed.

To locate the additional canal, the orifice is usually found just palatal to the orifice of the main mesio-buccal canal. With the course of the canal being toward the buccal aspect as it approaches the apex, it is suggested that a slight buccal curve be placed in the exploring instrument (37).

In 1973 Seidberg, *et al.* (38) in laboratory and in vivo clinical observations revealed that 38% of the mesio-buccal roots examined had a single canal from the pulp chamber to the apex; 37% had two pulp chamber orifices leading to separate canals that merged to a common apical foramen, 25% demonstrated two distinct canals and two distinct apical foramens. This is just another study which verifies the complexity of the mesio-buccal root canal system of the maxillary permanent first molar and emphasizes that care and effort needed to locate and treat these additional root canals.

Sergio Vigouroux, *et al.* in 1978 (39) studied the floor of the pulp chamber of the permanent maxillary molar to obtain information that would be used to search and find the root canals. The floor of the pulp was found exactly in the center of the tooth and approximately matched the contour at the same distance from mesial, distal, buccal, and lingual surfaces.

In 1990, Gilles, *et al.* (40) used electron microscope to examine the number, size, or location of the mesiolingual orifice in mesio-buccal root. The results of this study showed a higher incidence of two canals in maxillary first (81%) and second molars (59%) and separate mesiolingual orifices in both teeth than has been previously reported.

Kulild, *et al.* (41) found MB2 in the coronal half of 95.2% of the roots studied. 54.2% were located by hand instruments, 31.3% by use of a bur to trough, and 9.6% with the aid of a microscope. His study demonstrated that careful use of a bur increased the incidence in locating mesio-buccal canals, in vitro, from 54.2 to 85.5%. This study also showed that the careful use of a bur in the floor of the chamber should not lead to an increase in perforations.

In 1994, Fogel, *et al.* (42) used surgical telescopes, headlamps, and a modified access preparation which clinically aided in search for mesiolingual canals in mesio-buccal roots. He found high incidence (71.2%) of two treatable canals. Of these 71.2%, 31.7% had two separate apical foramina (Weine Type III) and 39.4% had two canals that joined (Weine Type II). In 28.9% cases only one canal was located.

Occurrence of the fourth canal in maxillary first molars varies from 18.6% (40) to 96.1% (43), depending on which method was used. John J Stropko, *et al.*, in 1999, stated that as operator became more experienced, scheduled sufficient time, routinely employed the dental operating microscope, and used specific instruments adapted for micro-endodontics, MB2 (second mesio-buccal) canals were located in 93% of first molars and 60.4% in second molars. Corcoran, *et al.* found similarity in their study

(44). Operator experience was found to improve the ability to locate and fill additional canals in maxillary first and second molars.

Wolcott, *et al.* (45) found significant difference in the incidence of a MB2 canal between initial treatments and re-treatments suggests that failure to find and treat existing MB2 canals will decrease the long term prognosis. The incidence of a MB2 in first molar re-treatments was 67% compared to a 59% incidence in initial treatments. Frank Vertucci (46) in his article described and illustrated root morphology. He stated that thorough understanding of the complexity of the root canal system is essential for understanding the principles and problems of shaping and cleaning, for determining the apical limits and dimensions of canal preparations, and performing successful microsurgical procedures.

Vertucci described another canal type that he designated as a type III canal. This type of canal starts as one canal, splits into two and then back into one canal at the apex.

Vertucci type IV canal was the same as the Weine Type III canal with two separate canals to the apex. Therefore his categorization (incidence) was Type I (45%), Type II (37%) and Type IV (Weine type III – 18%). Since then many laboratory techniques, like dye injection, have been used to determine the prevalence of MB2 canals.

Many radiographic methods have been explored to improve the accuracy of detecting MB2 radiographically. Walton (47) described a technique to alter the horizontal angulation of the radiographic beam to visualize the third dimension in a root. Martinez-Lozano, *et al.*(48) showed that altering the horizontal angulation of two periapical radiographs 20° and 40° improved visualization of objects that are superimposed over each other. Weine (49) indicated that the MB canal is often superimposed over MB2

which makes it difficult to visualize. MB2 is also close to the MB canal and has a smaller size. Goerig, *et al.* (50) used the 'Same Lingual Opposite Buccal' (SLOB) localization rule to determine the lingual from the buccal canal based on the change of direction of the x-ray beam and the movement of the canal or root on the second radiograph. SLOB rule states that the lingual canal, the most distant canal, will move in the same direction as the cone when a horizontal change is applied.

Filho, *et al.* (51) in 2009 investigated internal morphology of maxillary molars using cone beam computed tomography (CBCT) analysis. He demonstrated that operating microscope and CBCT have been important for locating and identifying root canals, and CBCT can be used as a good method for initial identification of maxillary first molar internal morphology.

In recent years, the development of micro-computed tomography (MCT) has gained increasing significance in study of hard tissues. MCT offers noninvasive reproducible technique for three-dimensional (3D) assessment of root canal systems and can be applied quantitatively as well as qualitatively. Furthermore, internal and external anatomy can be demonstrated simultaneously or separately. Somma, *et al.* (52) investigated *ex vivo* the root canal morphology of the MB root of maxillary first molar teeth by means of micro-computed tomography. He concluded that root canal anatomy is very complex: a high incidence of MB2 root canals, isthmuses, accessory canals, apical delta and loops was found.

Multiple articles indicate that CBCT may be used to evaluate root canal anatomy, however there is no evidence based criteria indicating what scan parameters are best for viewing small anatomical features like MB2 or for the difference clinical experience makes in evaluating CBCT scans. There are also no criteria for the use of CBCT as a laboratory standard.

The current research will focus on high resolution, limited field of view CBCT, hoping to resolve the following issues:

1. The ability to accurately detect the number of canals in mesio-buccal root of maxillary molars using CBCT.
2. The impact of CBCT voxel resolution on the ability to accurately detect the number of canals in mesio-buccal root of maxillary molars.

## **CHAPTER II**

### **STATEMENT OF OBJECTIVES AND HYPOTHESES**

#### **Study Objectives**

The purpose of this study is to investigate accurate detection of the correct number of root canals in the mesio-buccal root of the maxillary molar teeth using 3D imaging with cone beam computed tomography (CBCT) at different spatial resolution (isotropic voxel) settings. To determine the accuracy of CBCT images I compared detection rate of eight different observers with different level of experience to the ground truth, the anatomic cross-sections of mesio-buccal root of the maxillary molars utilized.

The specific aims of the study were to:

1. present descriptive information of overall accuracy of correct choice by raters in both original and repeat observations
2. compare the proportion of correct choices of the number of canals in mesio-buccal root of maxillary teeth among three groups of raters: endodontic faculty, second year endodontic residents and first endodontic residents for original observations



3. compare the proportion of correct choices of the number of canals in mesio-buccal root of maxillary teeth among three levels of resolution: 0.076 mm voxel, 0.1 mm voxel, 0.2 mm voxel for original observations
4. assess inter-rater reliability of the original measurements as measured by the intraclass correlation coefficient (ICC)
5. assess intra-rater reliability of the repeat measurements as measured by the intraclass correlation coefficient (ICC)

### **Study Hypothesis**

#### *Null Hypotheses ( $H_0$ )*

1. There is no statistically significant difference in the proportion of correct choices in mesio-buccal root of maxillary teeth among three groups of raters: endodontic faculty, second year endodontic residents and first endodontic residents for original observations
2. There is no statistically significant difference in the proportion of choices of the number of canals in mesio-buccal root of maxillary teeth among three levels of resolution: 0.076 mm voxel, 0.1 mm voxel, 0.2 mm voxel for original observations
3. The measures of inter-rater reliability of the original measurements as measured by the ICC do not differ from 0
4. The measures of intra-rater reliability of the repeat measurements as measured by the ICC do not differ from 0

*Alternate Hypotheses ( $H_1$ )*

1. There is a statistically significant difference in the proportion of correct choices in mesio-buccal root of maxillary teeth among three groups of raters: endodontic faculty, second year endodontic residents and first endodontic residents for original observations
2. There is a statistically significant difference in the proportion of choices of the number of canals in mesio-buccal root of maxillary teeth among three levels of resolution: 0.076 mm voxel, 0.1 mm voxel, 0.2 mm voxel for original observations
3. The measures of inter-rater reliability of the original measurements as measured by the ICC differ from 0
4. The measures of intra-rater reliability of the repeat measurements as measured by the ICC differ from 0

# CHAPTER III

## METHODS AND MATERIALS

### Overview

This observational cross-sectional *ex vivo (in vitro)* experiment was approved by an expedited review procedure through the Institutional Review Board (IRB), Human Studies Committee of the University of Louisville for a Specimen Study involving previously extracted human maxillary first and second molars (Appendix A).


Eight (8) dentist observers with varying experience in endodontics viewed a video that scrolled through one hundred and twenty three (123) CBCT cross sections performed on Kodak 9000 3D (Carestream, Marne-la-Vallée, France) of thirty one (31) extracted human maxillary first and second molars made at three different isotropic voxel dimensions or resolutions. Observers scored the presence or absence of MB2 canals as present or absent. This was compared to the ground truth by studying 2mm horizontal ground sections stained with methylene blue dye under a surgical operating microscope.

### Sample

The sample consisted of thirty one extracted human maxillary molars with closed apices acquired from the University of Louisville Oral and Maxillofacial Surgery department, faculty practice and the GPR (General Practice Residency). All teeth

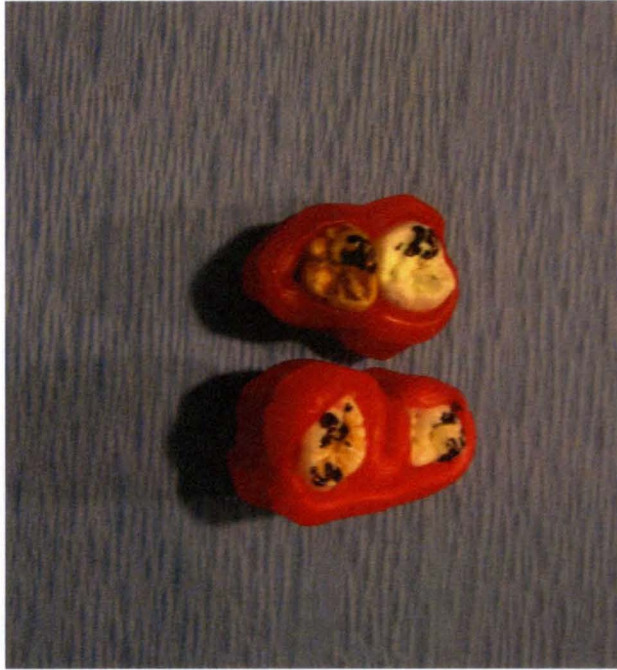originated from adults; the age, sex, race, and reasons for extraction were not recorded. The teeth were stored in 10% formalin for at least 7 days for disinfection and kept in this preservative for unknown number of weeks. Any molars with decay extending onto the root surfaces or with open apices were excluded from the study. Teeth which had large amalgam restoration had the material removed prior to study in order to avoid the scatter from metallic restorations. The teeth were removed from the storage medium and allowed to air dry for 24 hours.

Total of eleven models were prepared from which nine (9) models with three teeth (Fig.10) and two (2) models with two teeth embedded in Red Boxing Wax (Dentsply, York, PA) for a support medium (Fig.11). The teeth in each model embedded in wax was oriented so the palatal roots were on one side and buccal roots on opposite side and the teeth crowns were numbered from #1 through #31 respectively with a black sharpie marker for identification (Fig.12).




**FIGURE 10**

Nine Experimental Models with Three Teeth



**FIGURE 11**

Two Experimental Models with Two Teeth



**FIGURE 12**


Numbered crowns with a black sharpie marker (1-31) for identification



## **Imaging procedure for CBCT 3D acquisition**

Small field of view CBCT scans of each experimental model were performed using the Kodak 9000 3D (Carestream, Marne-la-Vallée, France). This machine is a true panoramic/CBCT hybrid capable of a number of radiologic examinations including, panoramic, segmented panoramic, maxillary sinus and TMJ projections

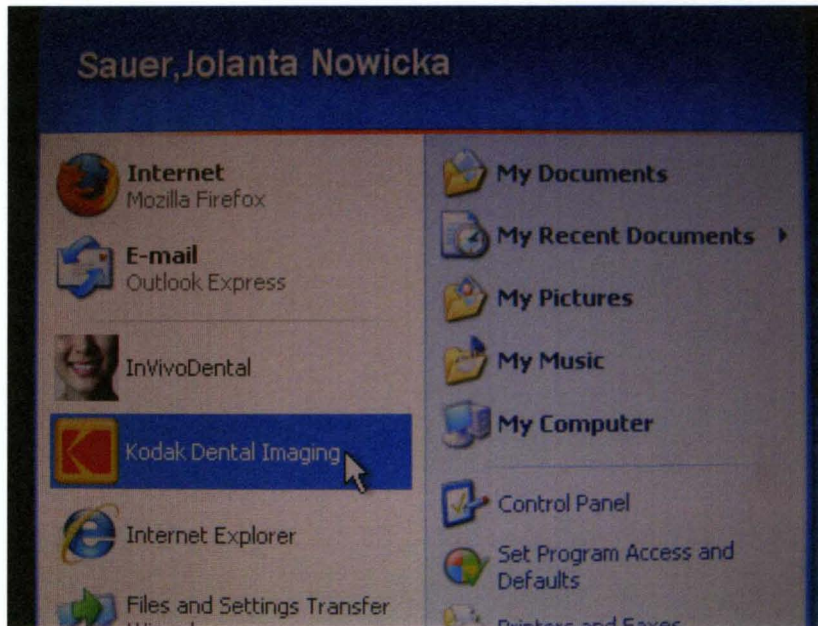
- 1) Prior to CBCT imaging, the acquisition computer must be turned on first after which the imaging platform is then turned on (Fig. 13).



**FIGURE 13**

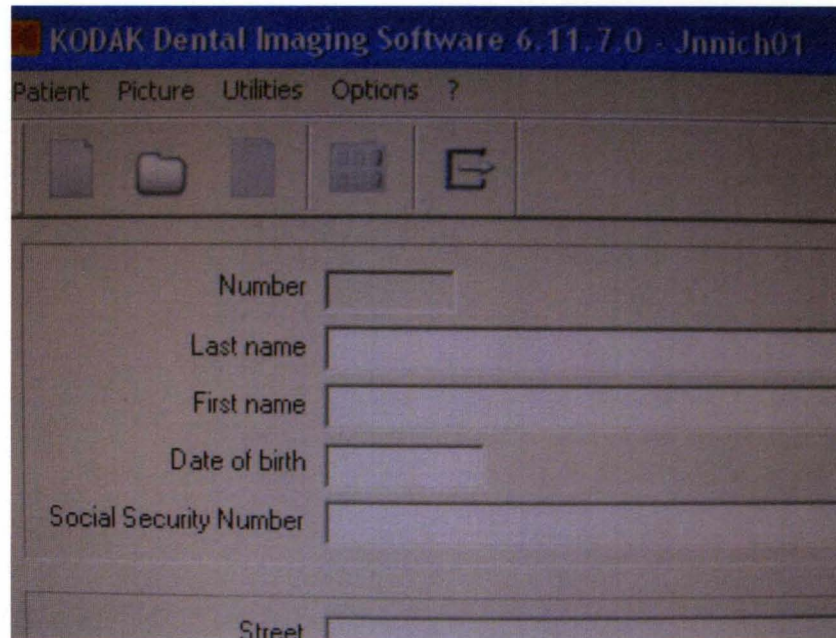
Screenshot of acquisition computer turned on

- 2) Next the KODAK dental imaging icon on the screen is selected to activate the KODAK Dental Imaging Software (Version 6.11.7.0, Kodak 9000 3D, Carestream, Marne-la-Vallée, France) (Fig. 14-15).



**FIGURE 14**

Selection of KODAK Dental Imaging Software




**FIGURE 15**

Screen shot of initial start up screen of KODAK Dental Imaging Software

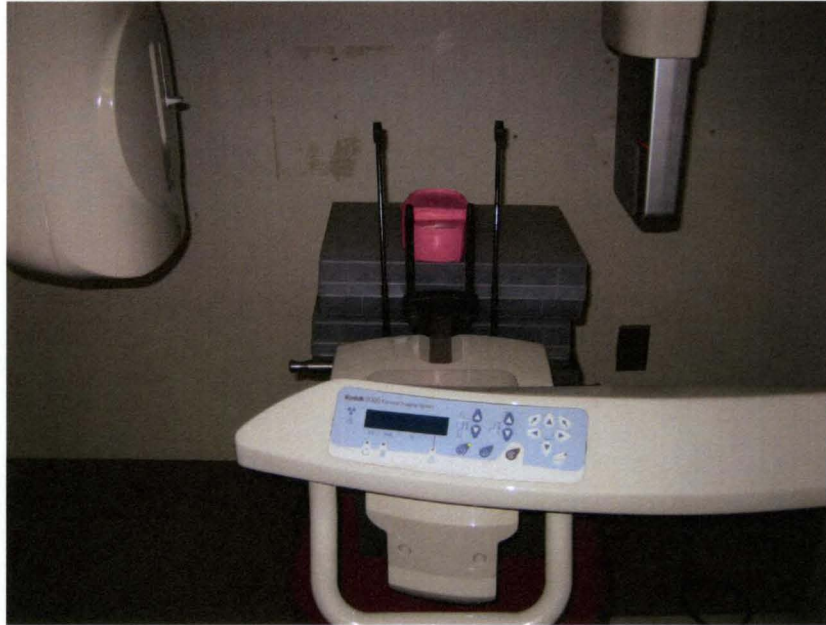

- 3) The demographic data of the patient is then entered into the appropriate fields including the patient's number, last and first name, date of birth, social security number, address, phone number and comments. If the patient is of record, then under "PATIENT", the option "FIND" is selected and the existing patient database is identified. For purposes of our study each experimental model was entered into the computer system under "Sauer" name.
- 4) For all images, the experimental models, one at the time, were immersed in water in the plastic container (pink denture box) with the crowns down and roots up – mimicking the "real" orientation of maxillary teeth in the mouth (Fig. 16). The water level in the denture box was up to 2 cm above the apex of the teeth to provide soft tissue equivalent attenuation. The container with the water and immersed teeth was positioned on a support in an approximate position between the detector and the x-ray generator near the cephalostat (Fig. 17).



**FIGURE 16**


Placement of experimental models on the support prior to acquisition



**FIGURE 17**

Arrangement of a plastic container with experimental model immersed in water


- 5) The experimental models were oriented such that the occlusal plane of maxillary teeth was parallel to the scan rotation plane. This was achieved by using three laser guided lights to correct the positioning of the experimental model in the vertical, mid-sagittal and, horizontal orientation. Crowns of the extracted teeth were placed just below the horizontal laser guide beam, while mid-sagittal and vertical laser beams were in the middle of the experimental model (Fig. 18-19).



**FIGURE 18**

Demonstration of the vertical and horizontal laser lights

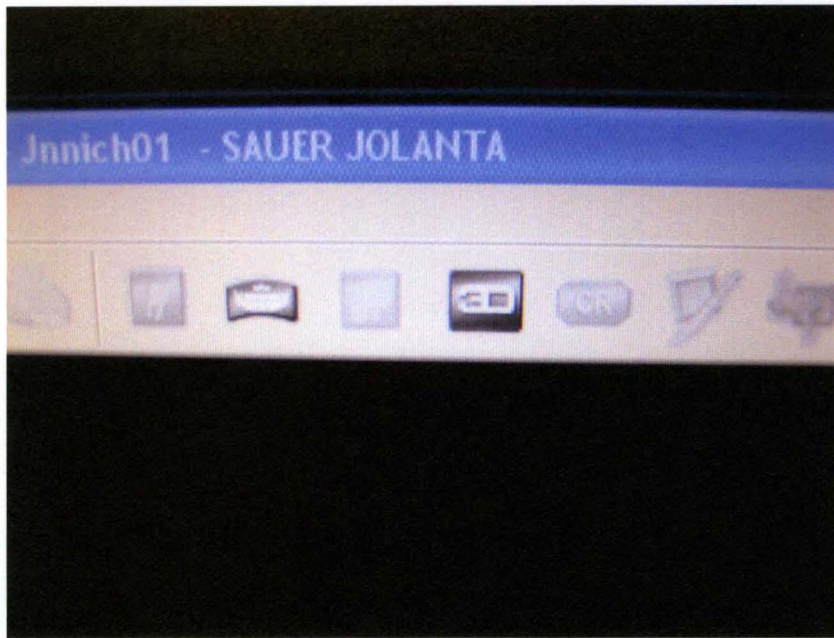




**FIGURE 19**

Demonstration of the vertical and mid-sagittal laser lights

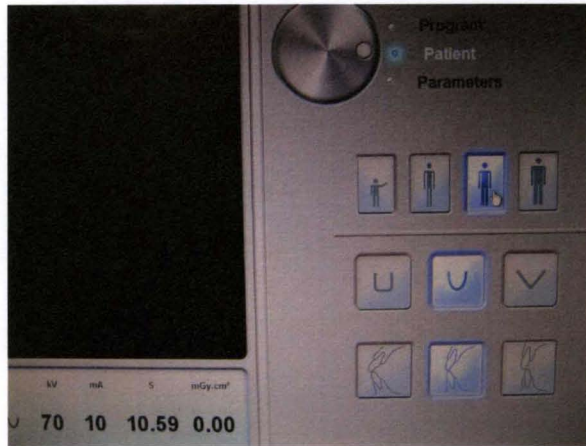
- 6) After the experimental model was positioned in the cephalostat it is necessary to alter the fulcrum of the CBCT and center it in the volume to be scanned. This is accomplished by accessing the “3D” imaging console (Fig. 20). 3D acquisition is achieved by selecting the “3 D” icon on the task bar.



**FIGURE 20**

Initial interface of the KODAK Dental Imaging Software

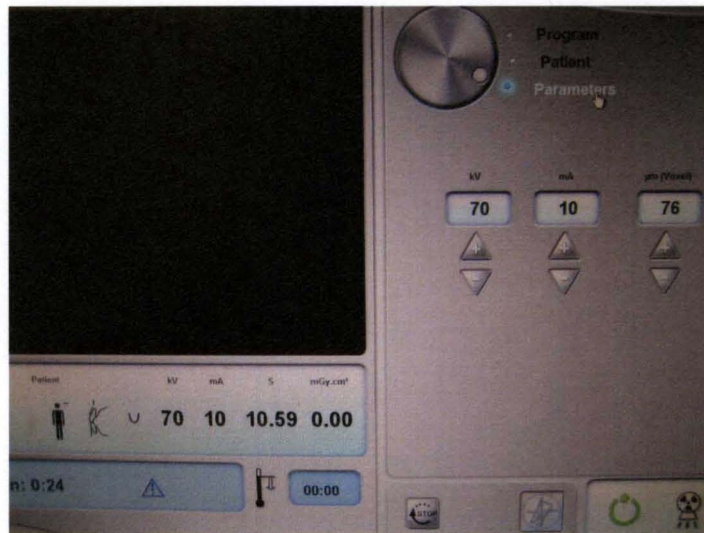
- 7) The software provides the operator two (2) methods to control exposure parameters. Exposure can be adjusted according to patient type (“Patient”) or individual exposure factors including mA and kVp can be adjusted (“Parameters”). We adjusted the technical parameters of exposure using the 3 exposure variables present on the “Patient: selection: 1) Size of the patient (4 options - child, small adult, medium sized adult, large sized adult), 2) Shape of dental arch (3 options – square, “U”, and “V” shaped arch forms) and, 3) Position of anterior teeth (3 options – protrusive, normal interincisal angle and, steep interincisal angle). We empirically determined that the optimal image was obtained with a “U” shaped arch, medium adult exposure and normal anterior incisal edge occlusion (Fig. 21).



**FIGURE 21**

Parameters used under “Patient” selection for each experimental model exposure

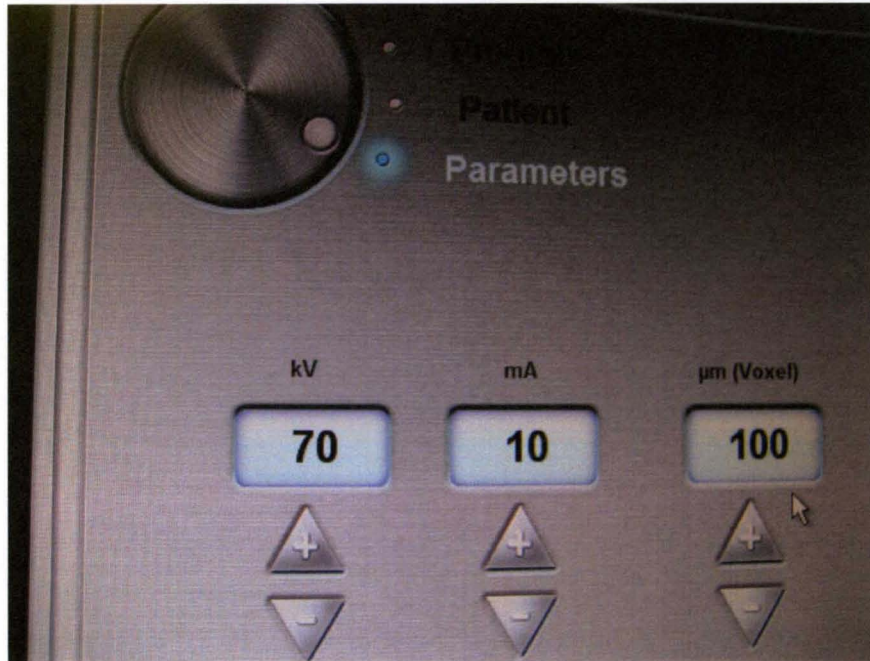
- 8) An initial scout film was performed on each specimen to verify that the entire tooth was in the scan region. All experimental models were then scanned at one of the three voxel resolutions: 0.076mm (Fig. 22), 0.1mm (Fig. 23) and, 0.2mm (Fig. 24).



**FIGURE 22**


Voxel resolution 0.076 mm





**FIGURE 23**

Voxel resolution 0.1 mm



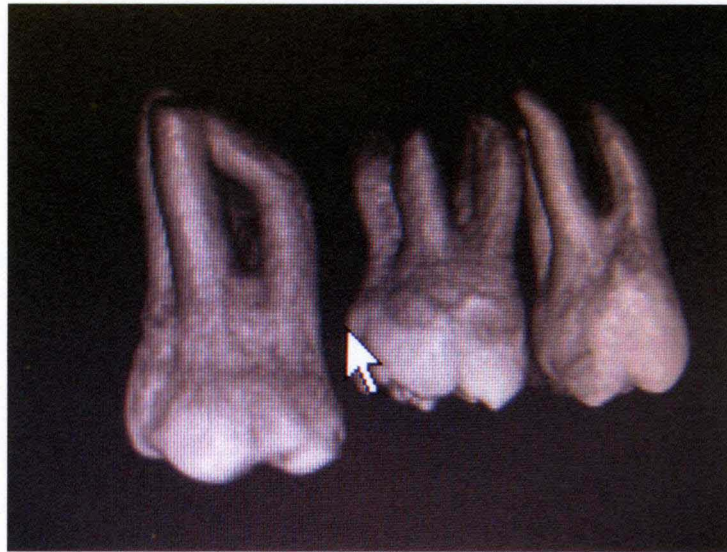**FIGURE 24**

Voxel resolution 0.2 mm

- 9) After selecting the required parameters the launching of the X-Ray by remote control. To hold the exposure until the end of the acquisition. The image appears on the screen.

### **Image Reconstruction and Display**

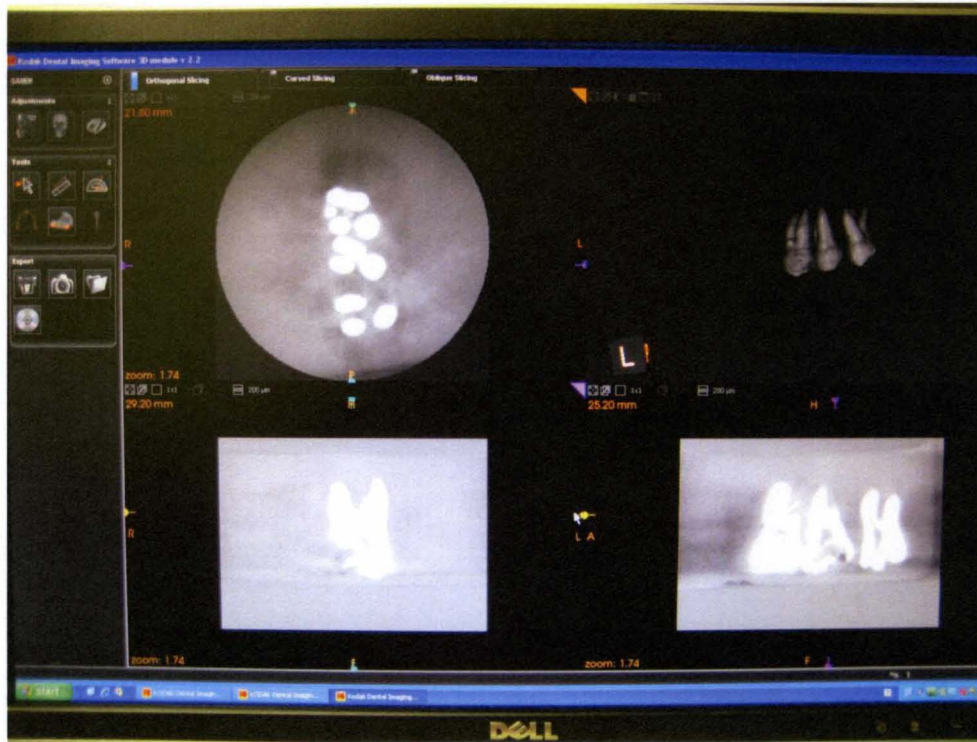Primary reconstruction of the data was automatically performed immediately after acquisition and took less than a minute. Secondary reconstruction occurred in “real time” and provided contiguous color correlated perpendicular axial, coronal and sagittal 2D MPR slices, with isotropic voxels in each orthogonal plane (Fig. 25-26).



**FIGURE 25**

Image on KODAK Dental Image Software

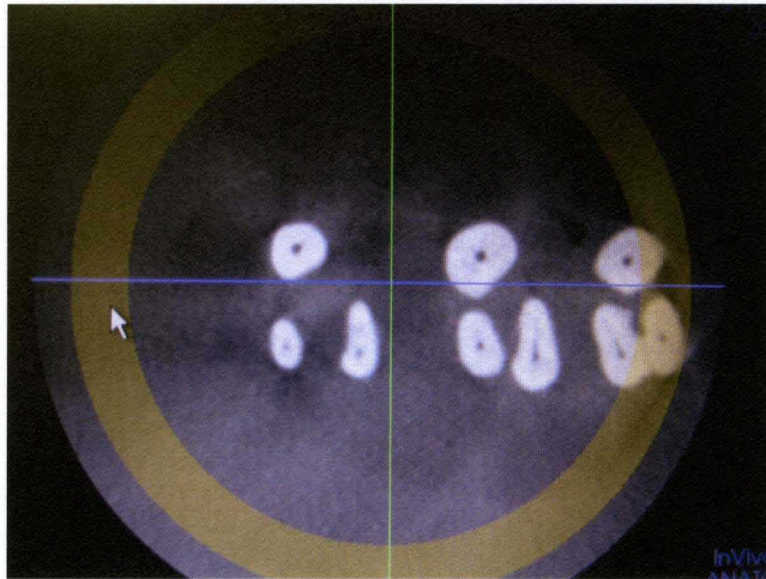



**FIGURE 26**

Screenshot of dataset using KODAK Dental Imaging Software in orthogonal display mode

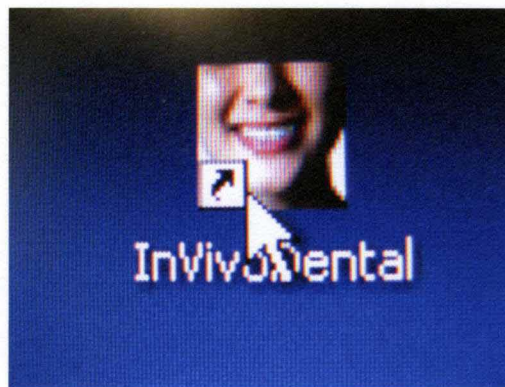
CBCT reconstructions can be displayed in three orthogonal planes simultaneously, axial, sagittal and coronal. For our study we only used the orthogonal plane. To establish the cross section, the cross sectional tool is selected from the menu options at the top of the scan screen in order to scan through the tooth (Fig. 27)



**FIGURE 27**

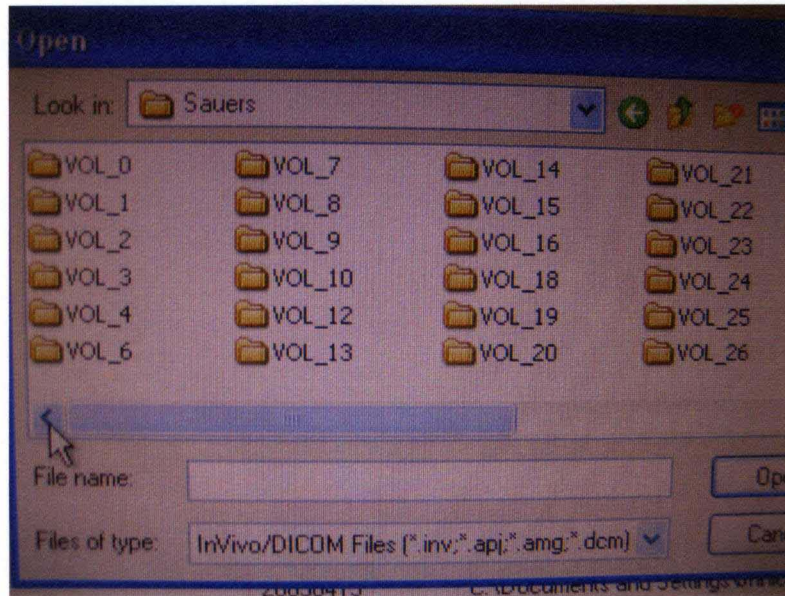
KODAK Dental Imaging Software cross sections of experimental models oriented such that palatal roots are oriented to the top of the screen

Each SFOV volumetric dataset was exported in DICOM multiframe format and imported into *InVivoDental* software (Anatomage, San Jose, CA) (Fig 27-28).



**FIGURE 27a**

*InVivoDental* software Icon (Anatomage, San Jose, CA)

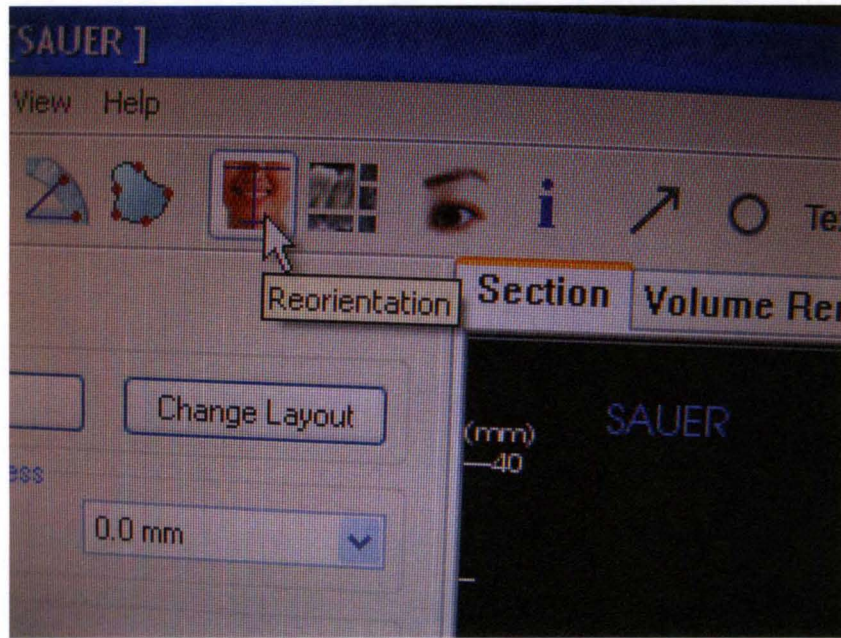


**FIGURE 28**

Screenshot of opening *InVivoDental* (Anatomage) software

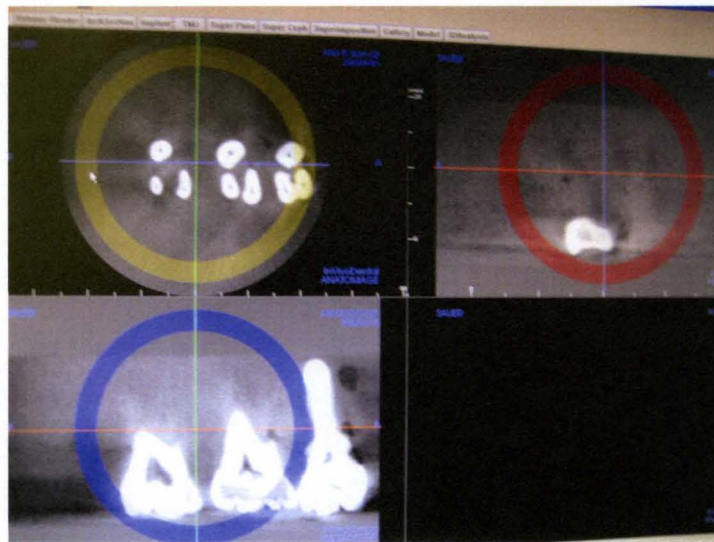
After importing DICOM files from Kodak into *InVivoDental* software the reorientation of teeth (Fig. 29) in each of the experimental models occurred such that palatal roots were oriented so they appear on the top of the screen (Fig. 30-31)





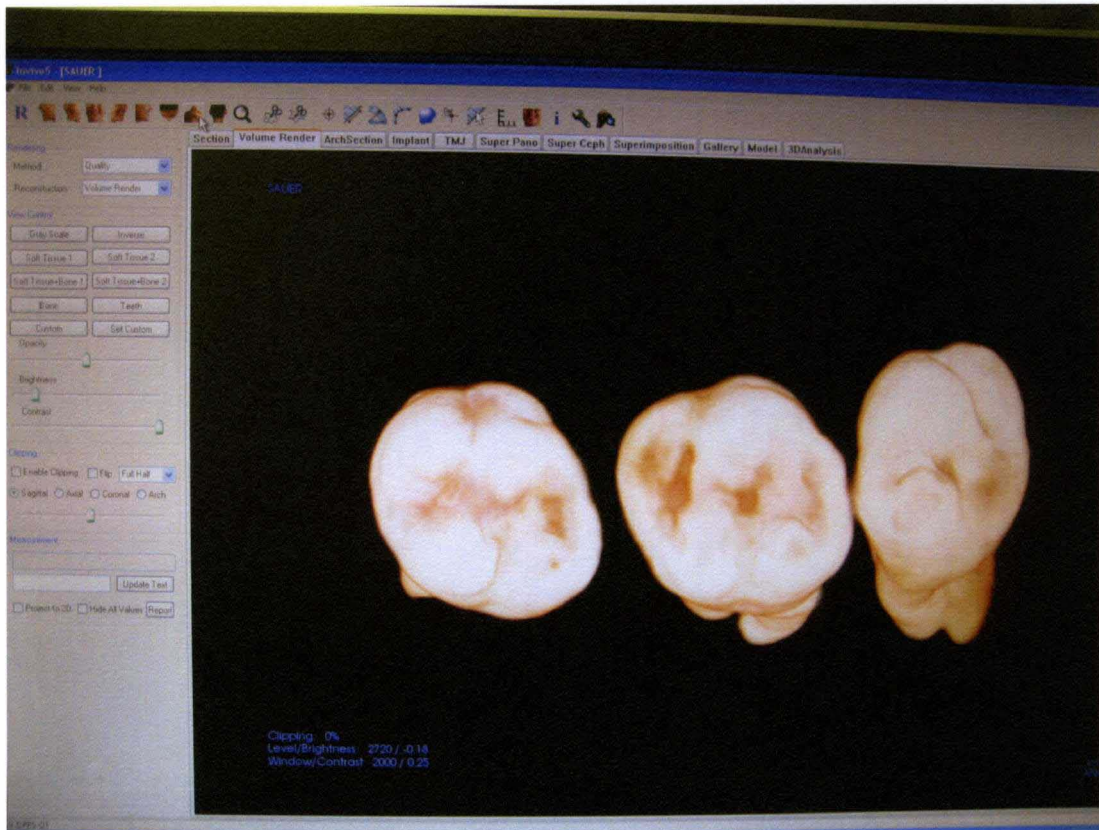**FIGURE 29**

Reorientation of the experimental models on the screen



**FIGURE 30**

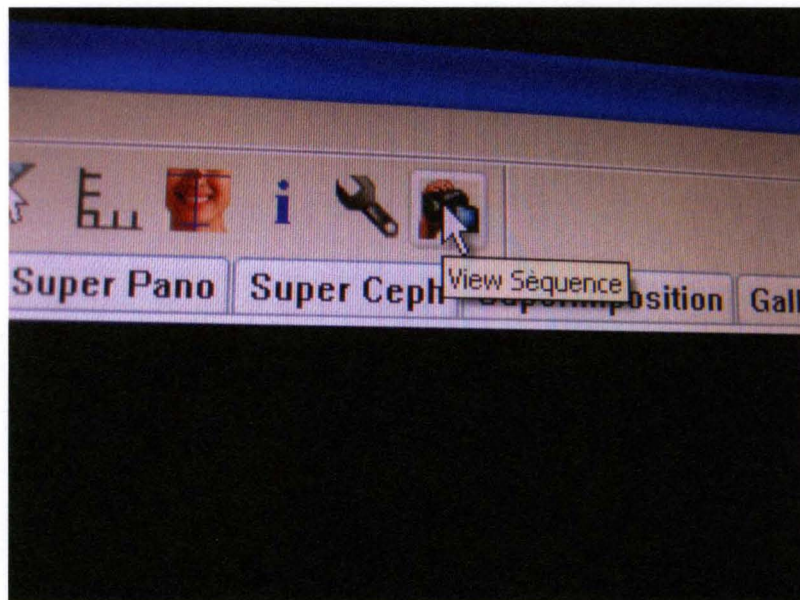
Reorientation of the experimental models on the screen



**FIGURE 31**

Reorientation of the experimental models on the screen in *InVivoDeantal* software

An advantage to evaluating CBCT data is the ability for the observer to dynamically interact with the volumetric data by scrolling through the cross sections. In my study the cross-sections were presented to raters as a video rather than selected or a contiguous strip of static images. These videos were made using the screen capture (Fig. 32).

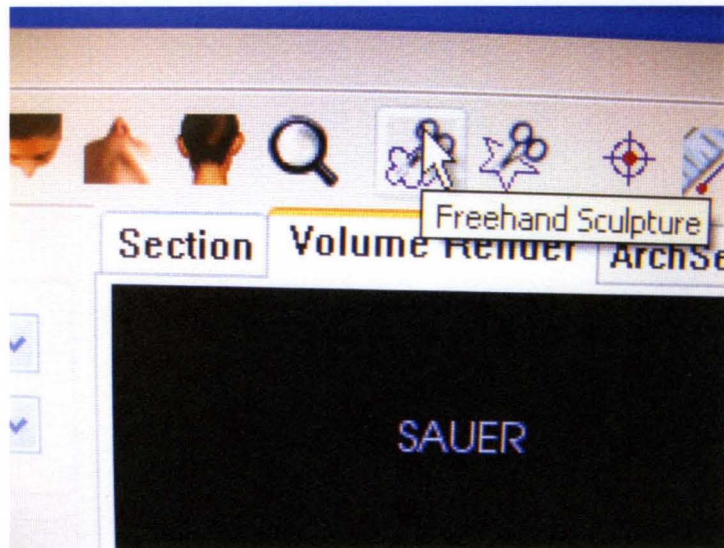


**FIGURE 32**

*InVivoDental* Video software Icon (Anatomage, San Jose, CA)

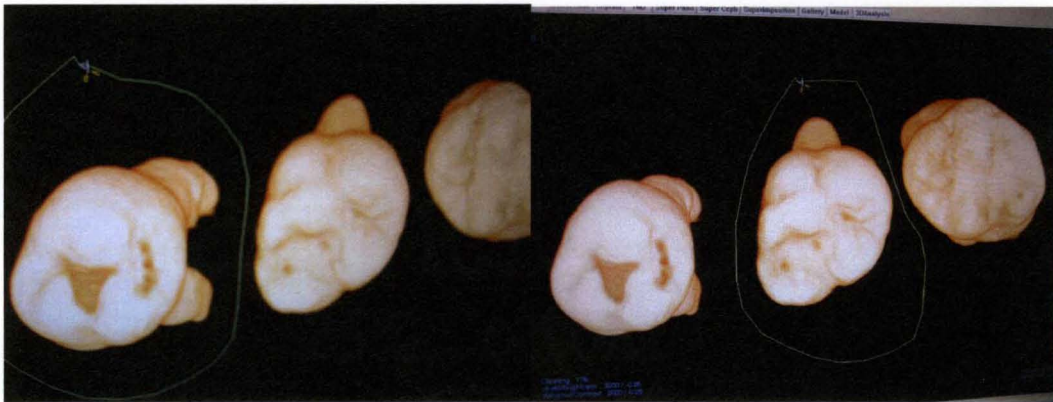Using the Anatomage software (Fig. 33) and the mouse driven cursor, a circle was drawn around each tooth (Fig. 34) in order to separate them so there will be only one tooth at the time on the screen (Fig. 35).





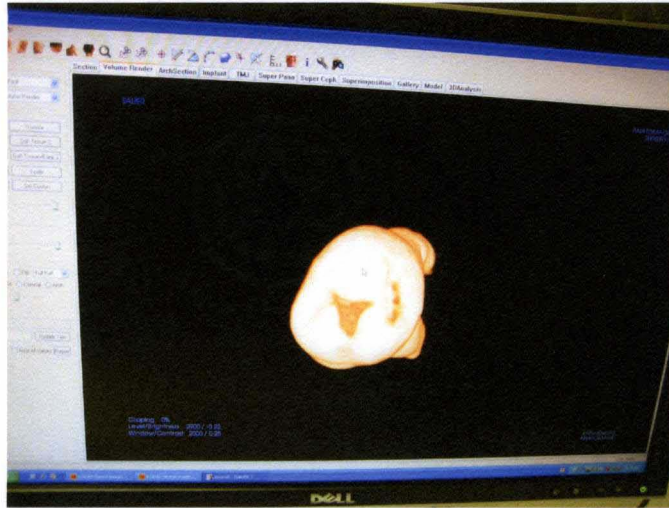
**FIGURE 33**

Icon used to separate teeth so there will be one tooth at the time on the screen



**FIGURE 34**

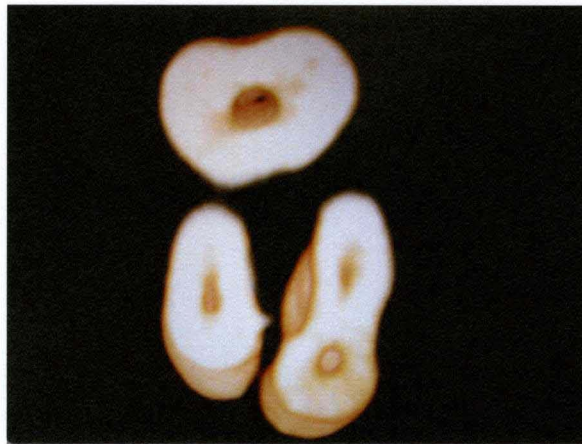Drawing around each tooth to separate them



**FIGURE 35**

Single tooth on the screen

Each tooth at each resolution was placed with the cross section at 100% magnification (Fig.36).



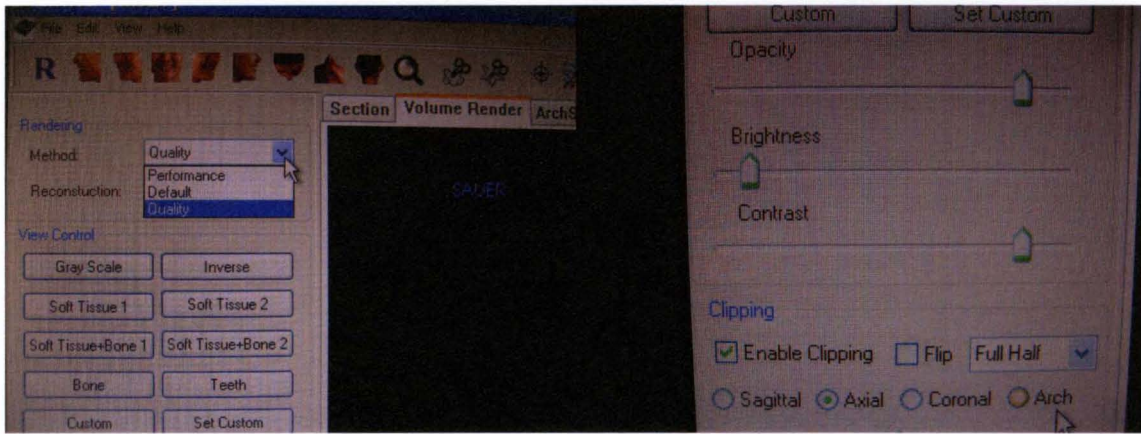
**FIGURE 36**

Cross section of tooth



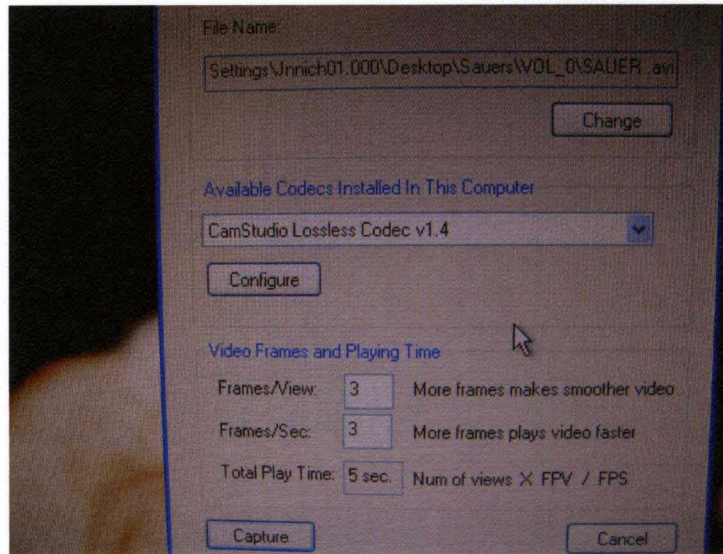
Each scan took from 12 to 25 seconds depending on the length of the tooth roots.

After appropriate rendering method, opacity, brightness and contrast (Fig. 37) we saved all videos using the “customized” option according to the settings as demonstrated in Fig. 38. These settings were determined by conversations with Dr. Doug Chenin from Anatomage.



**FIGURE 37**

“Customized” settings



**FIGURE 38**

### Video Capture

Thirty one (31) teeth were scanned at three different resolutions. Total of ninety three (93) videos were generated. Ten (10) videos from each resolution were repeated to determine intra-observer variability [31 teeth x 3 resolutions = 93 videos + 30 repeat videos = 123 videos]. The digital videos were saved in the \*.avi format to a portable Kingston hard drive.

### Data collection

Using the website: [www.random.org](http://www.random.org) (Fig. 39) random sequence was generated for 123 numbers [31 teeth x 3 resolutions = 93 videos + 30 repeat videos = 123 videos] (1-123) to determine the order of the videos in the final video folder (appendix B).

A second random sequence of numbers was generated to determine the 10 repeat videos from each of three folders with 3 different resolutions (Fig. 40).

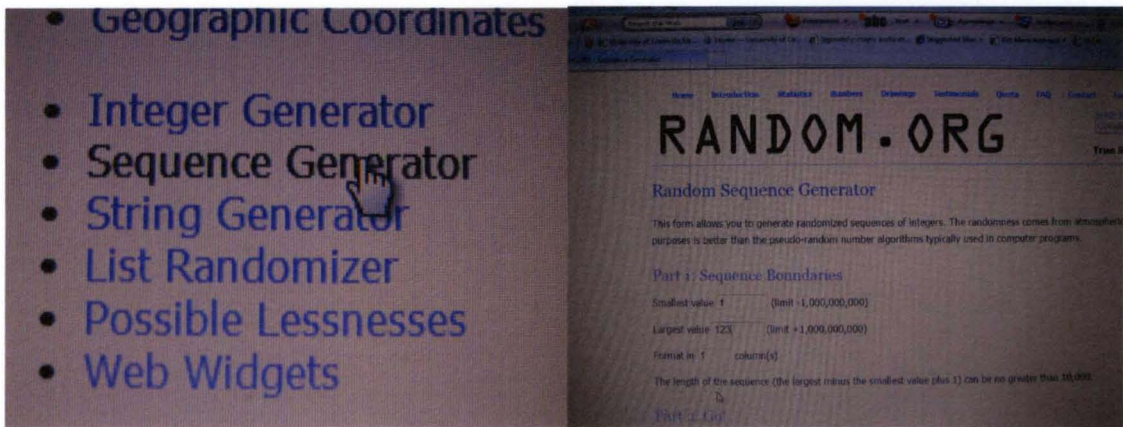


FIGURE 39

Random Sequence Generator

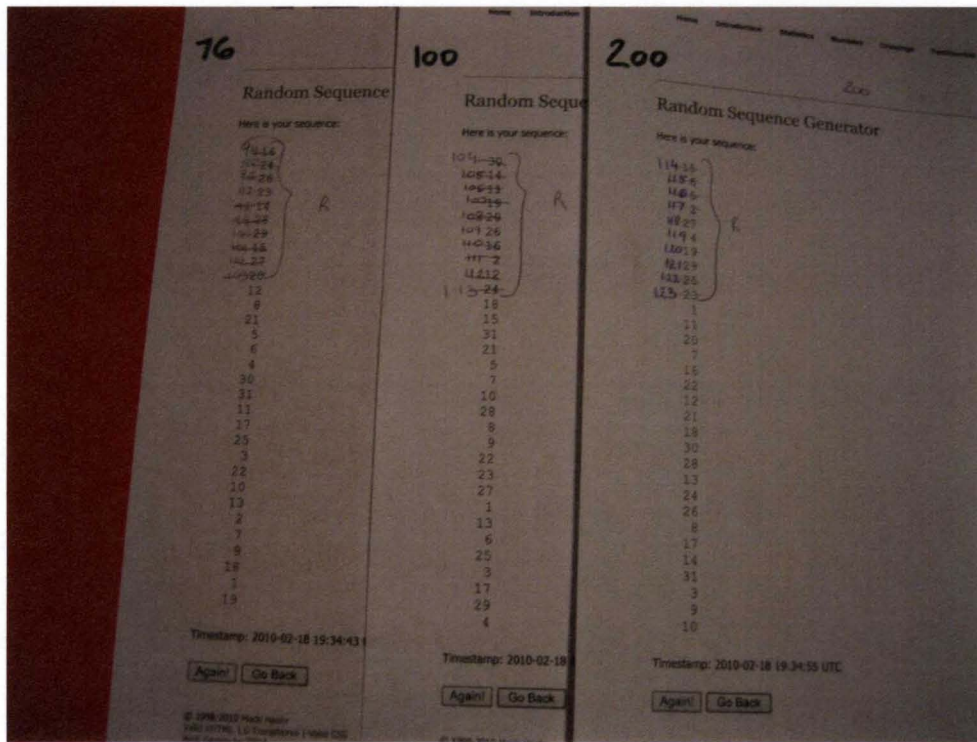


FIGURE 40

Random sequence of numbers generated to determine the repeat 10 videos from each folder of three different resolutions

## **Video observations**

Individual video folders with three different resolutions (including repeats) were combined into one final video folder where 123 videos were stored in \*.avi format using previously *InVivoDental* (Anatomage, San Jose, CA) software.


Five endodontic residents (two second year and three first year residents) and three endodontic faculty members were asked to independently evaluate the presence or absence of MB2 canals in maxillary molars. The observers were given written instructions (Appendix C) (same instructions were placed on desktop) as well as observers assessment form to fill out (Appendix D). Observers were watching the 123 videos on the same DELL Computer terminal in a “literature review room”. Videos were played on a Windows Media Player (Microsoft, Redmond WA 98052). Upon viewing, the observers were asked to rate the presence or absence of MB2 canals using a two point confidence scale:

- 1 – One canal detected,
- 2 – Two or more canals detected.

Each observer studied the 123 videos resulting in 123 ratings per observer (Fig. 41).

Thus 984 ratings (123 Ratings x 8 Observers) were obtained (Appendix B).





**FIGURE 41**

Observers' assessment form

**Determination of Anatomic Truth**

To evaluate the anatomic truth is important to describe: tooth sectioning, staining cross-sections and microscopic evaluations confirmed by picture taking.

**Tooth sectioning**

After completion of the observers assessments each tooth was removed from the experimental models and soaked in 30% Sodium Hypochlorite solution for a minimum of 24 hours. The MB root of each tooth was cleaned with a denture brush and hand perio scaler (Hu-Friedy, Chicago, IL). After drying the teeth were set in red wax and labeled. After 2 days of dry time the MB root of each tooth were measured and marked with pin point marker in order to obtain 2 mm horizontal cross-sections (Fig. 42).

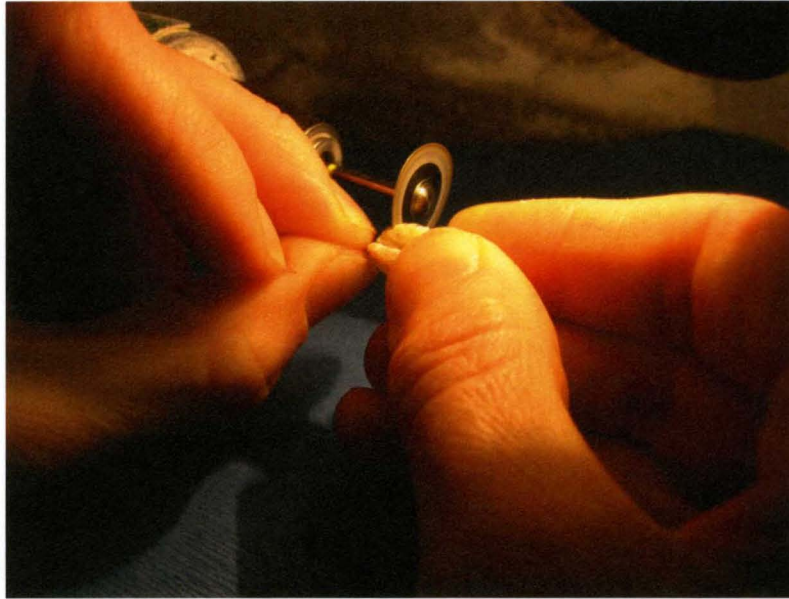

**FIGURE 42**

Marked 2 mm horizontal cross-sections

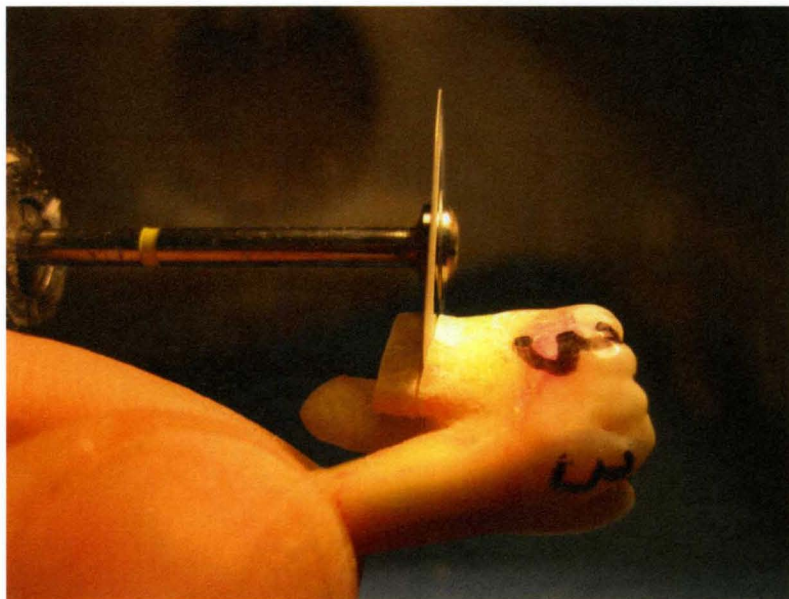
Each tooth section was initiated from the apex and proceeded coronally until the furcation was reached.

The tooth crown was secured between right and left hand of researcher on the support (Fig. 43) and a diamond disc was used with high speed of saw (Baldor Polishing Lathe with Wells Quick Chuck, 3450 RPM) to section the mesio-buccal root horizontally in 2mm increments (Fig. 44). Three to six sections were made of the MB root depending on the root length. The tooth sections were placed on red wax with the rest of the tooth (Fig. 45).



**FIGURE 43**


Making 2 mm horizontal sections of mesio-buccal root of molar



**FIGURE 44**

2 mm horizontal sections of mesio-buccal root of molar





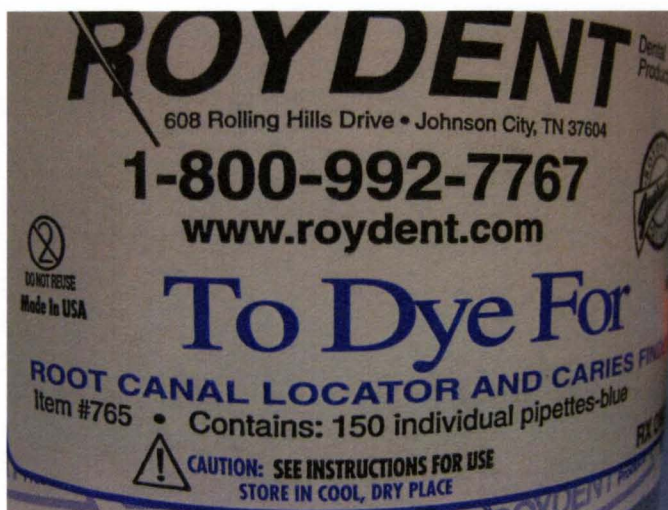
**FIGURE 45**

Teeth with their 2 mm cross-sections

### **Staining of the cross-sections**

The 2 mm cross-sections of each tooth root embedded in red wax were stained with methylene blue dye (Roydent, Johnson City, TN) to highlight the canal space (Fig 46).

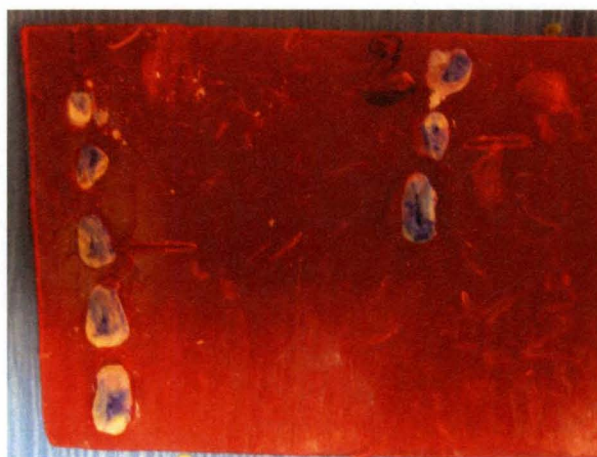




**FIGURE 46**

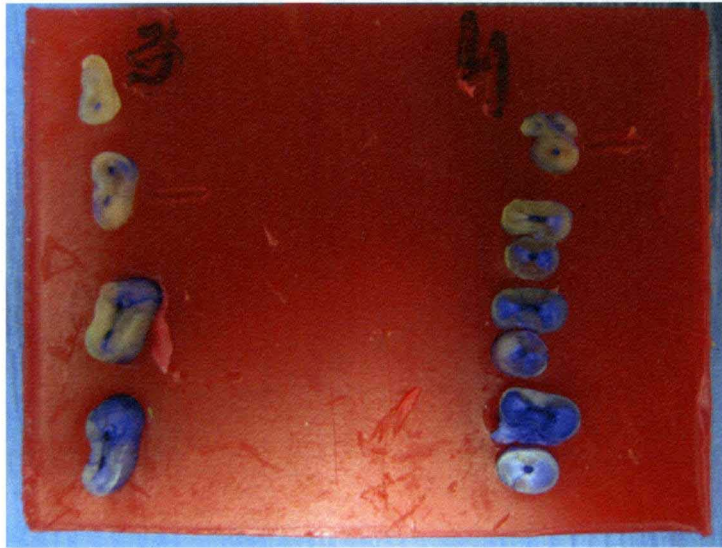
Root canal locator dye

The root sections were photographed using Cannon Power Shot SD 450 camera to show all the sections together. All sections were stained but only one section was evaluated by the microscope (Fig.47- 61).



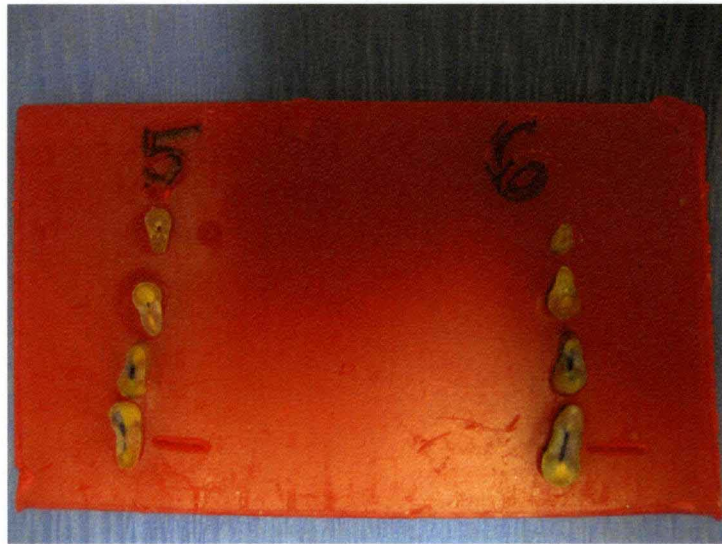
**FIGURE 47**

Photographic view of cross-sections teeth 1 & 2



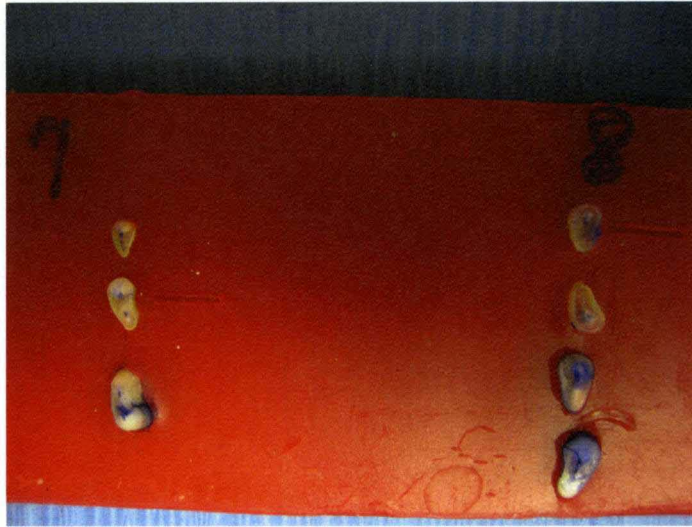
**FIGURE 48**

Photographic view of cross-sections teeth 3 & 4




**FIGURE 49**

Photographic view of cross-sections teeth 5 & 6



**FIGURE 50**

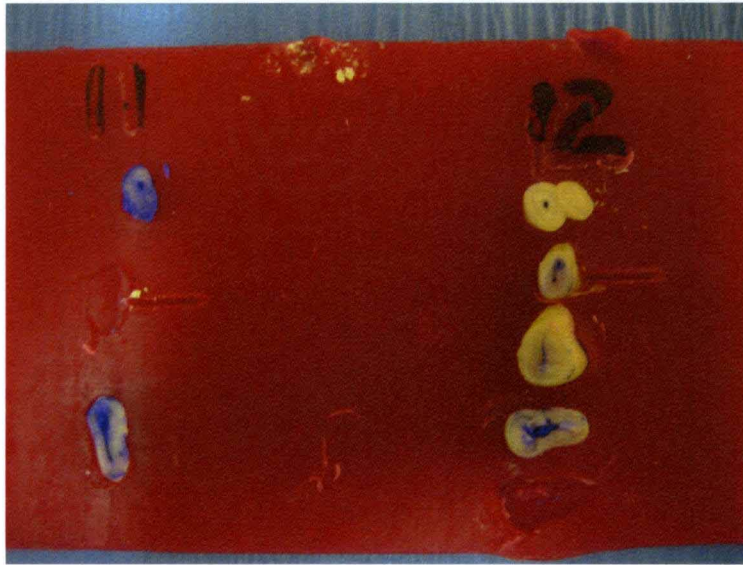
Photographic view of cross-sections teeth 7 & 8



**FIGURE 51**

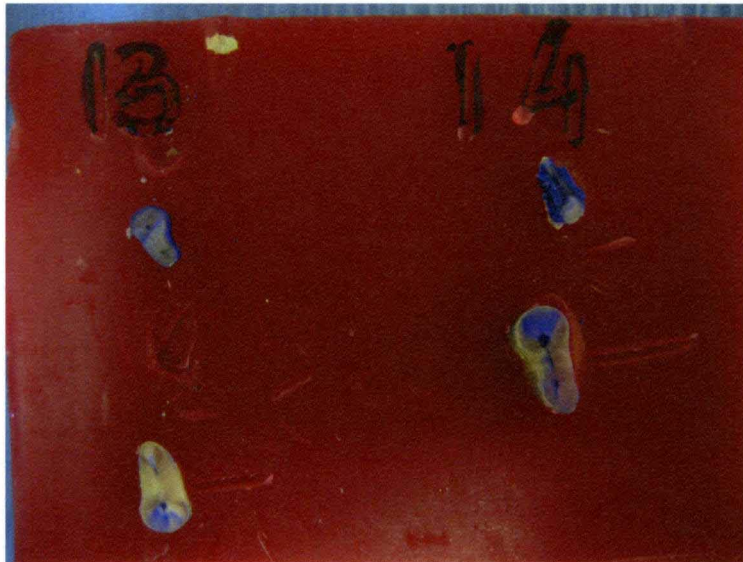
Photographic view of cross-sections teeth 9 & 10





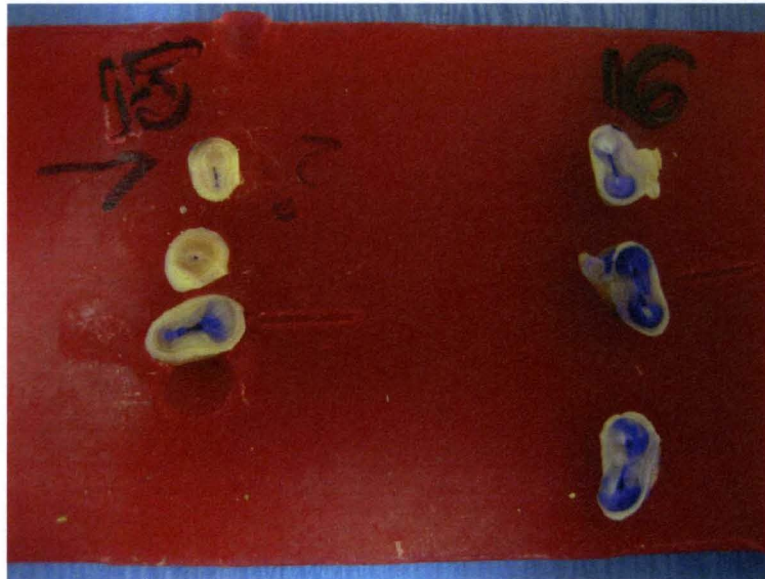
**FIGURE 52**

Photographic view of cross-sections teeth 11 & 12



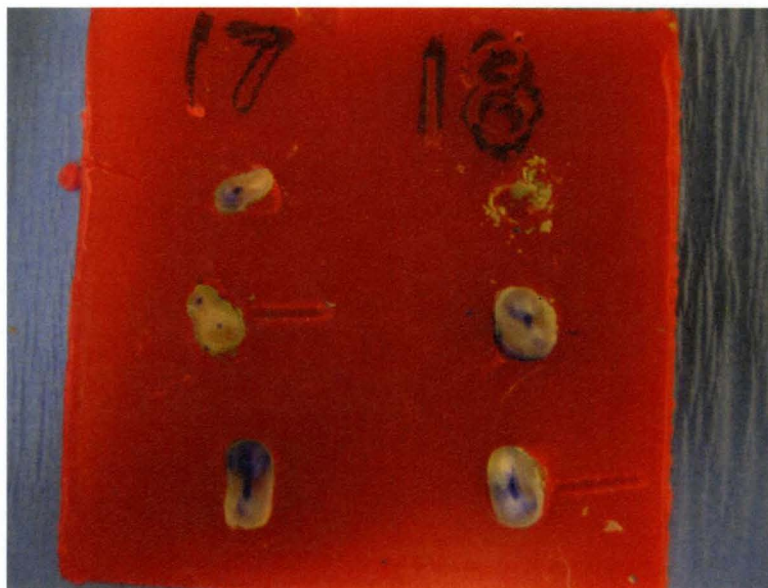
**FIGURE 53**

Photographic view of cross-sections teeth 13 & 14



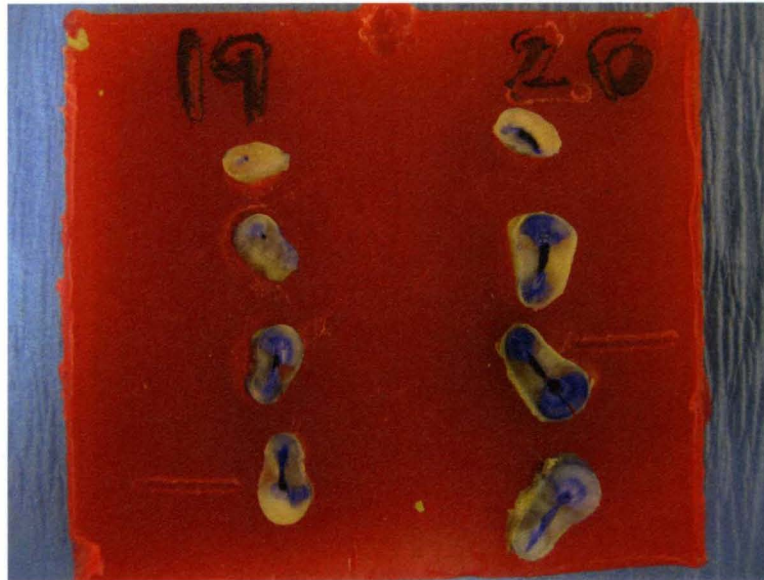
**FIGURE 54**

Photographic view of cross-sections teeth 15 & 16




**FIGURE 55**

Photographic view of cross-sections teeth 17 & 18



**FIGURE 56**

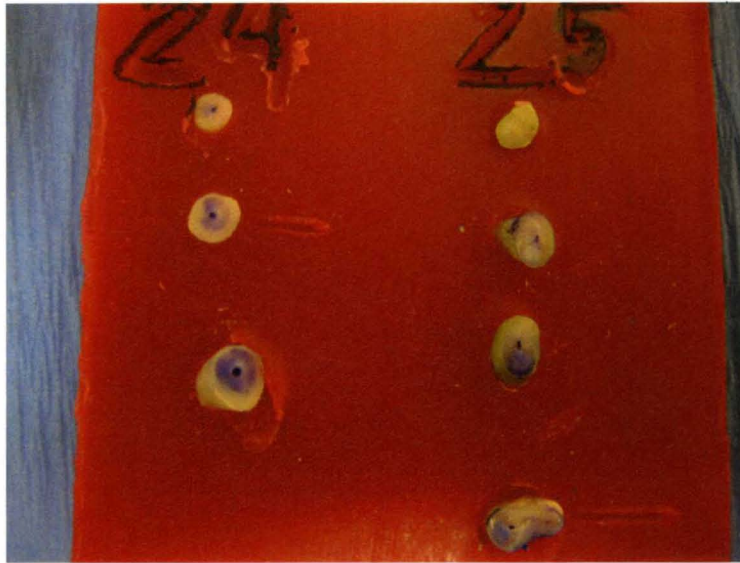
Photographic view of cross-sections teeth 19 & 20



**FIGURE 57**

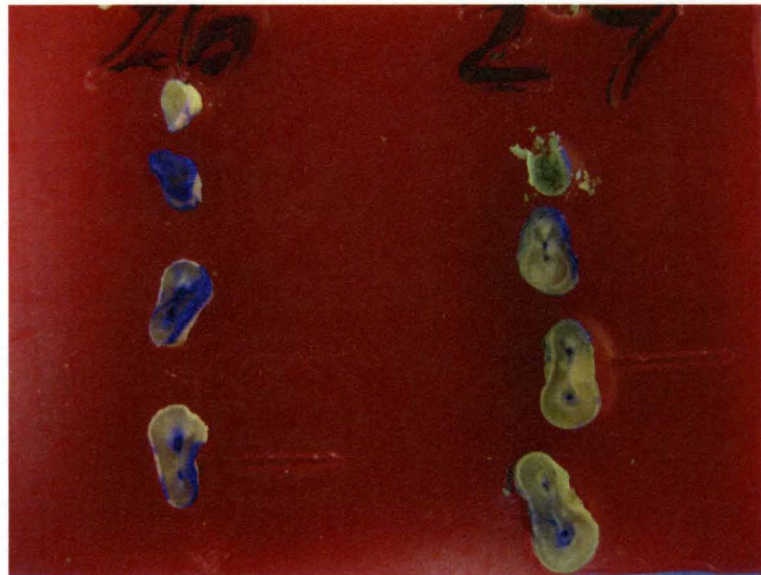
Photographic view of cross-sections teeth 21, 22 & 23





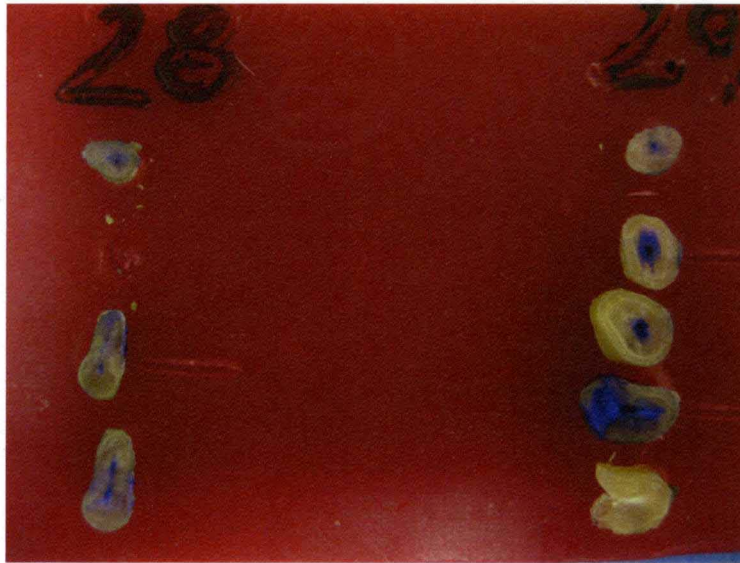
**FIGURE 58**

Photographic view of cross-sections teeth 24 & 25



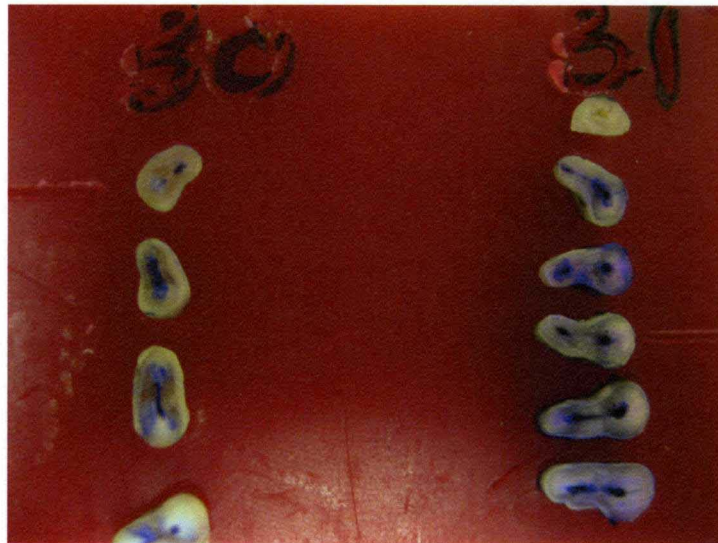
**FIGURE 59**

Photographic view of cross-sections teeth 26 & 27



**FIGURE 60**

Photographic view of cross-sections teeth 28 & 29




**FIGURE 61**

Photographic view of cross-sections teeth 30 & 31



### **Microscopic evaluation**

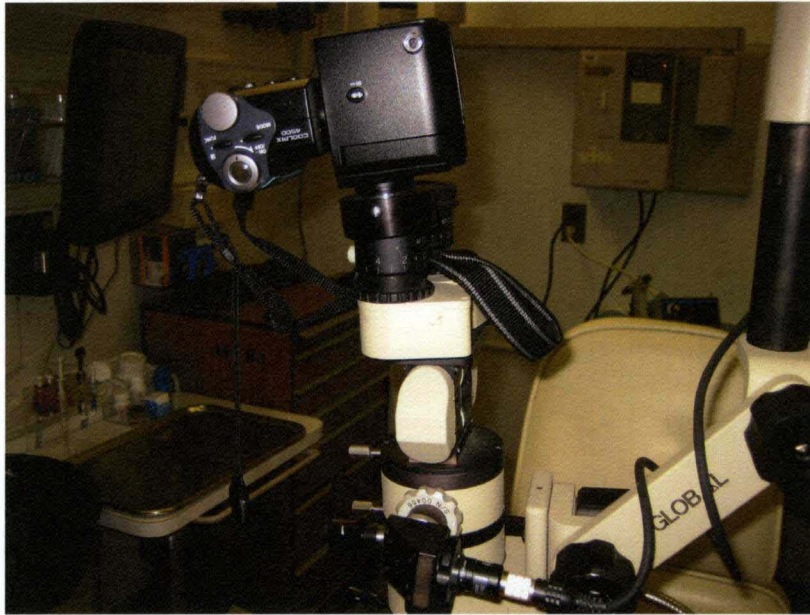Each root cross-section was viewed under a global surgical operating microscope (Global Surgical Co., St. Louis, MO 63122) (Fig. 62) to determine the presence of one or two canals.



**FIGURE 62**

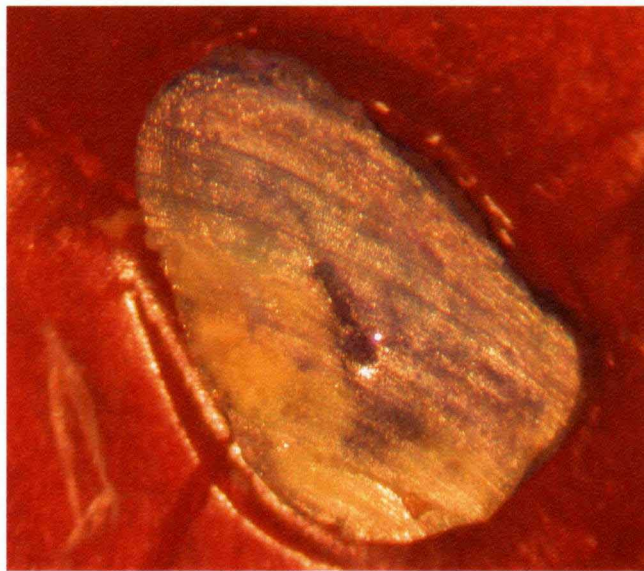Cross-sections under microscope

One resident and one faculty member blinded to the tooth number or identification carefully examined the sections to determine the true number of canals present. The results of the two observations were compared for consistency. There were 5 inconsistent answers so final answer was given based on two additional endodontic residents evaluation the questionable sections. Photographs were taken through the microscope using the Nikon COOLPIX 4500 digital camera (Fig. 63-94).



**FIGURE 63**

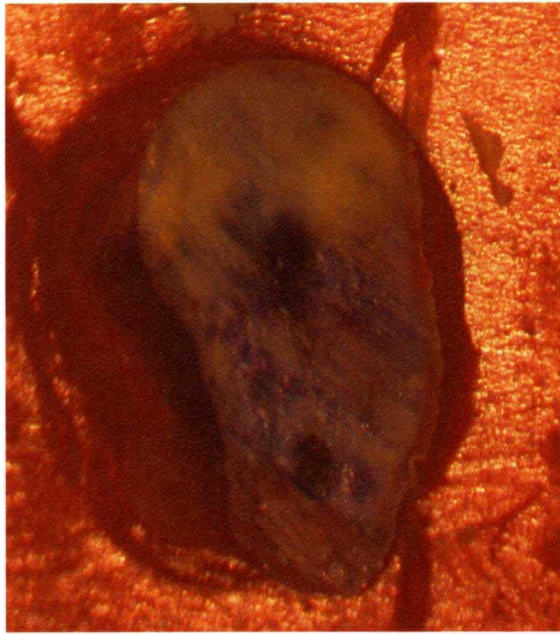
Microscope and camera set up



**FIGURE 64**

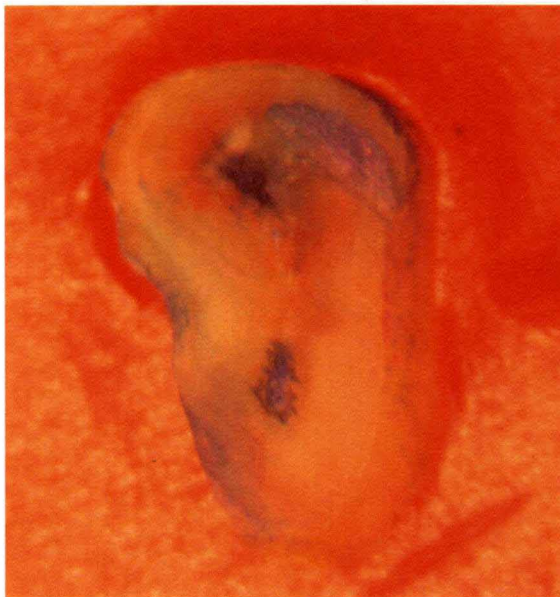Microscopic view of tooth #1





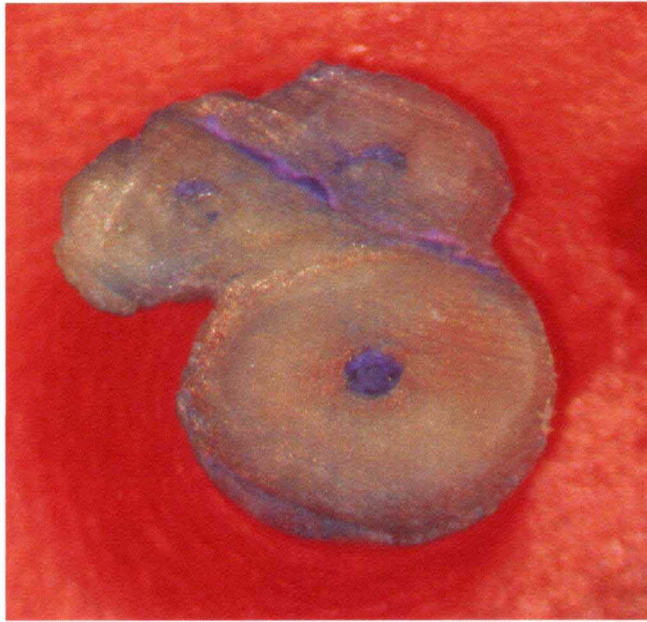
**FIGURE 65**

Microscopic view of tooth #2



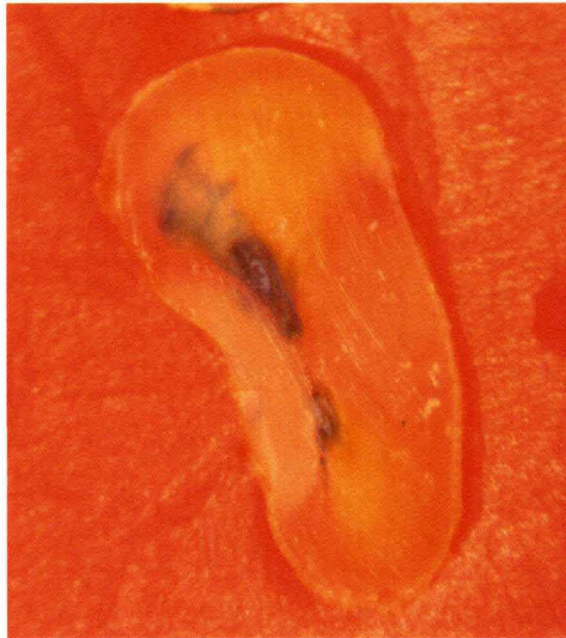**FIGURE 66**

Microscopic view of tooth #3



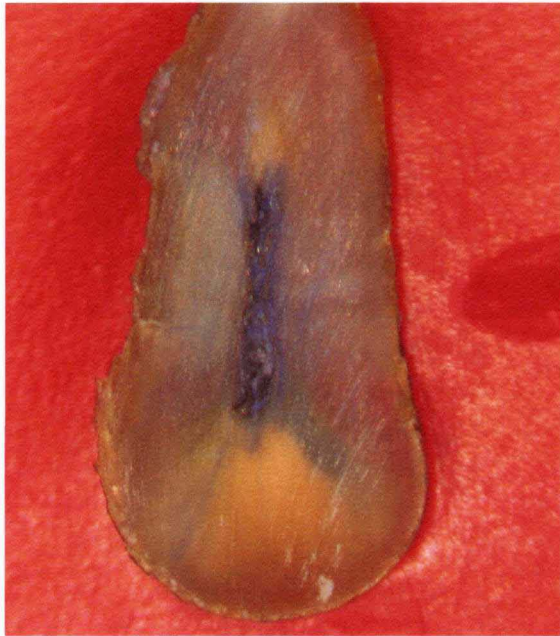**FIGURE 67**

Microscopic view of tooth #4



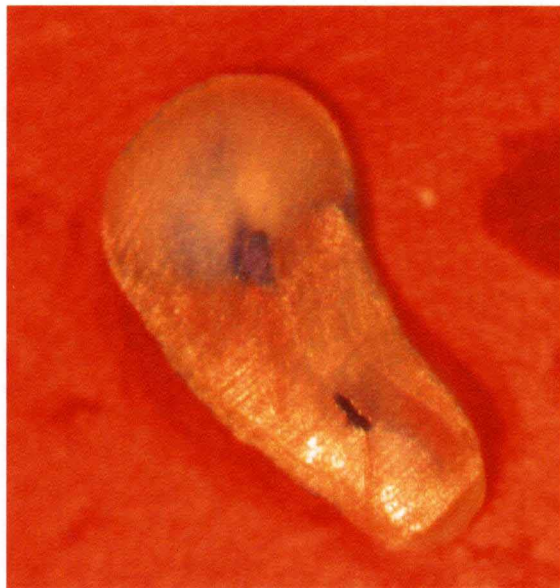**FIGURE 68**

Microscopic view of tooth #5



**FIGURE 69**

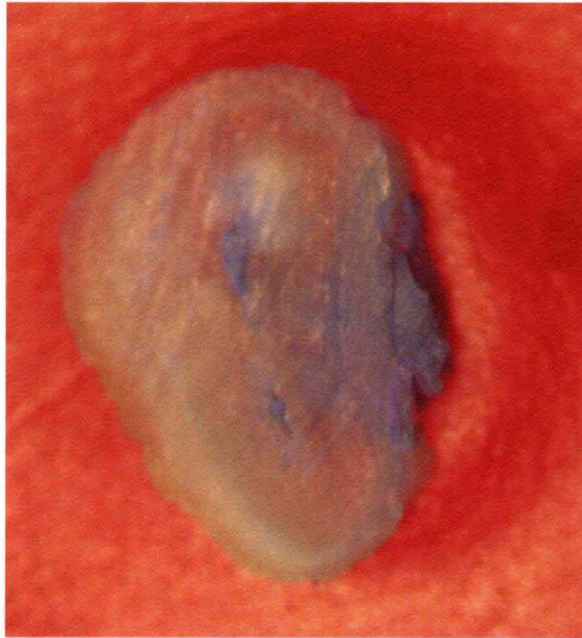Microscopic view of tooth #6



**FIGURE 70**

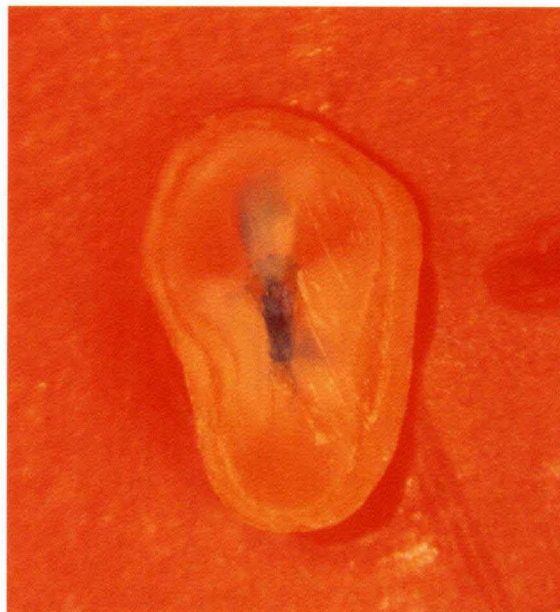Microscopic view of tooth #7





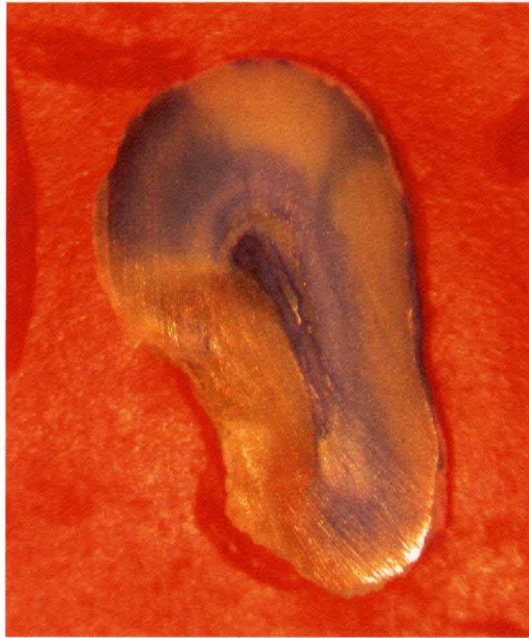
**FIGURE 71**

Microscopic view of tooth #8



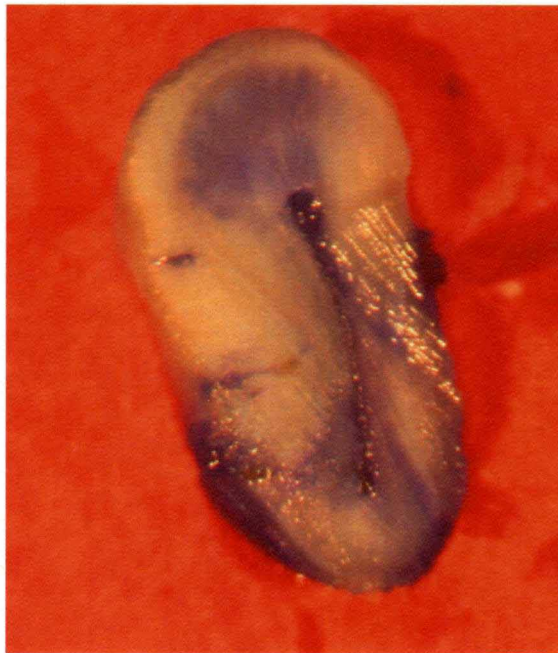**FIGURE 72**

Microscopic view of tooth #9



**FIGURE 73**

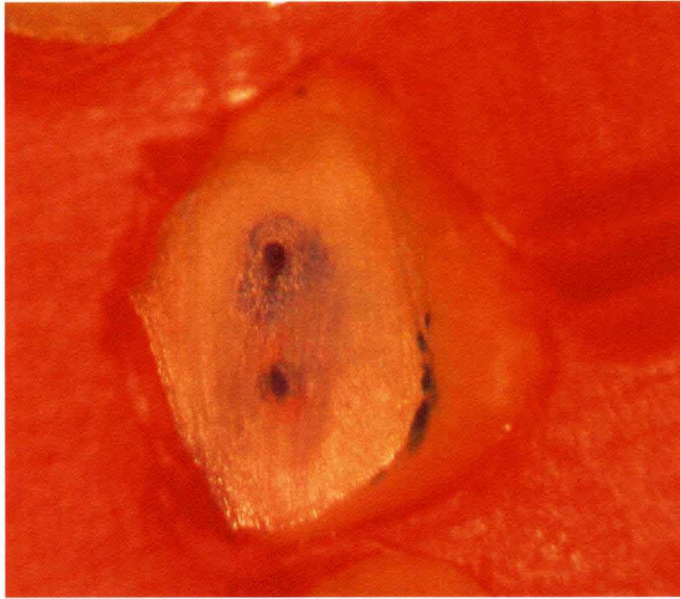
Microscopic view of tooth #10



**FIGURE 74**

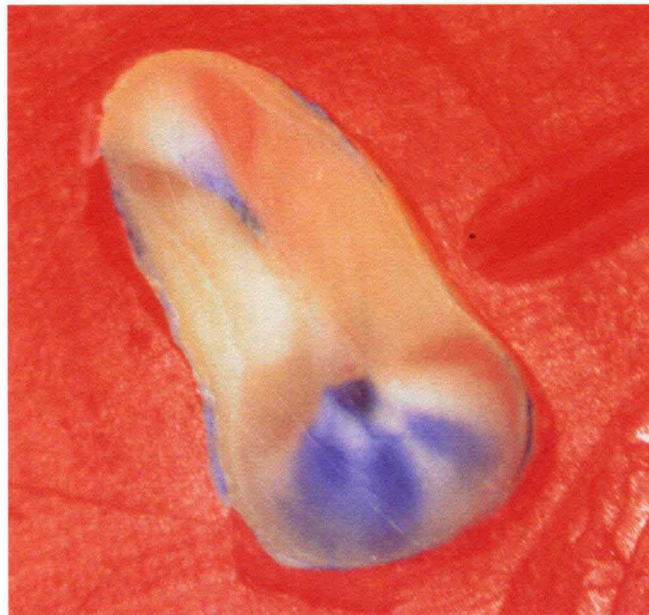
Microscopic view of tooth #11





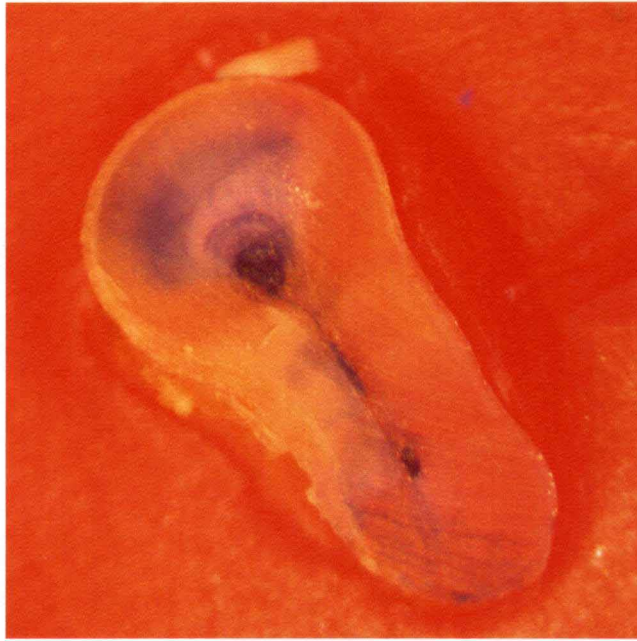**FIGURE 75**

Microscopic view of tooth #12



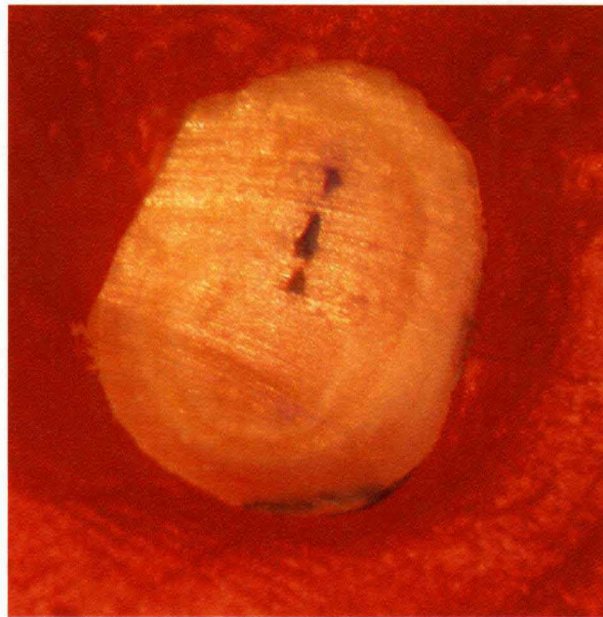
**FIGURE 76**

Microscopic view of tooth #13



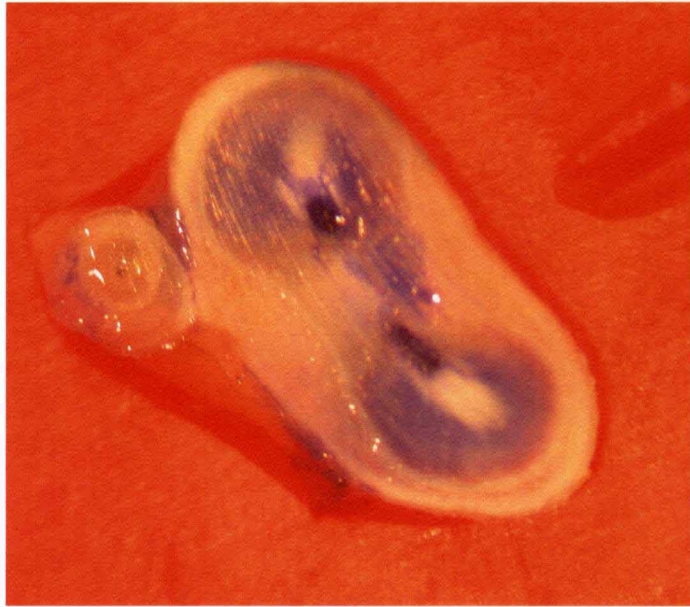**FIGURE 77**

Microscopic view of tooth #14



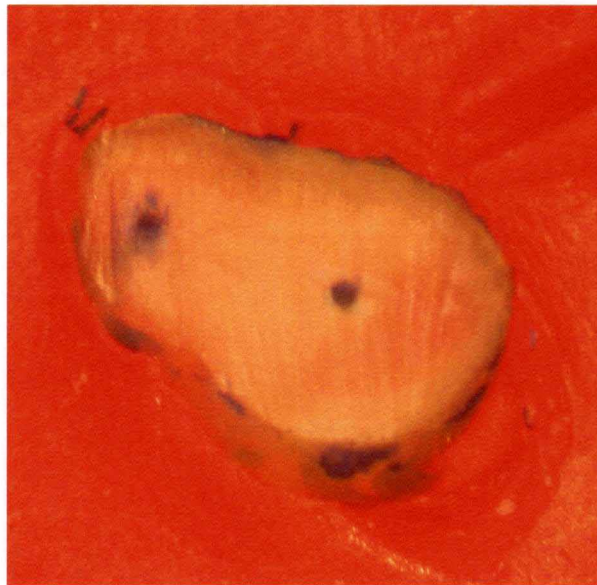**FIGURE 78**

Microscopic view of tooth #15



**FIGURE 79**

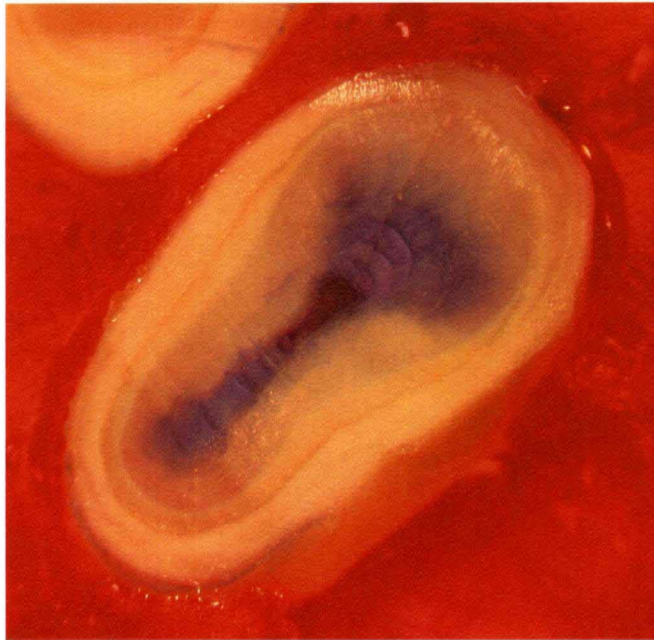Microscopic view of tooth #16



**FIGURE 80**

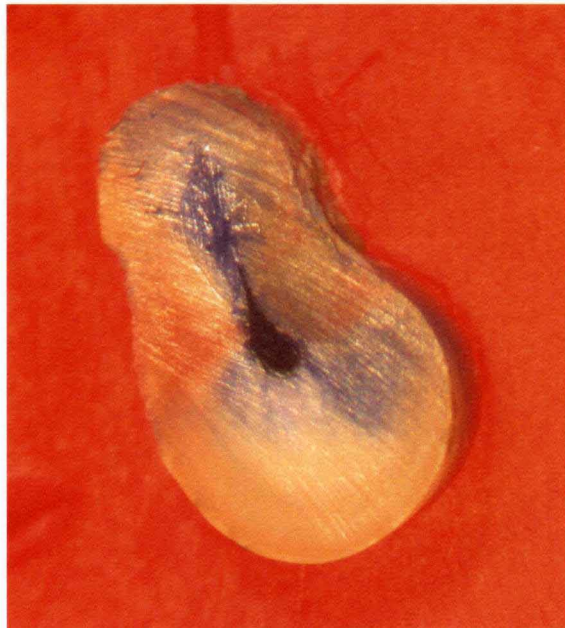Microscopic view of tooth #17





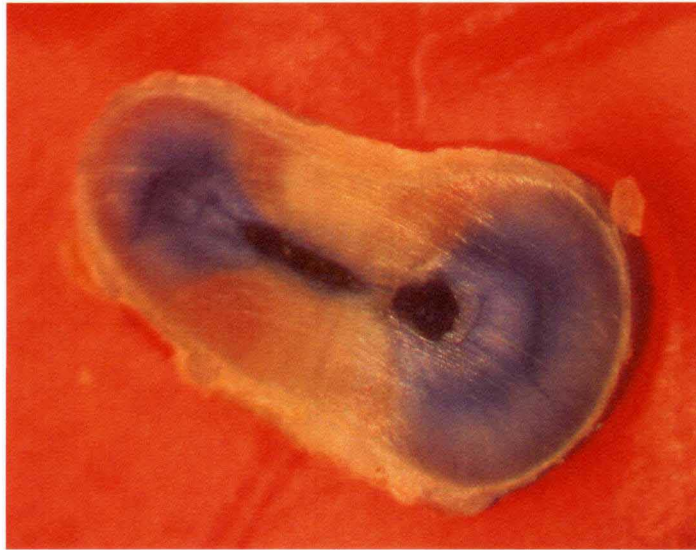
**FIGURE 81**

Microscopic view of tooth #18



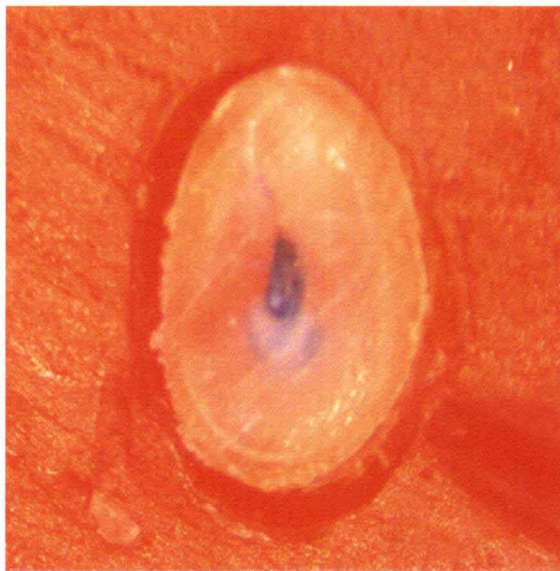**FIGURE 82**

Microscopic view of tooth #19



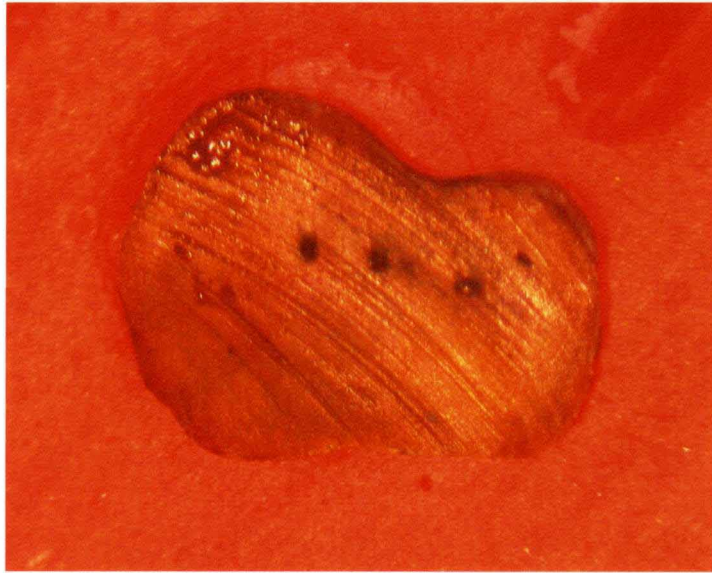
**FIGURE 83**

Microscopic view of tooth #20



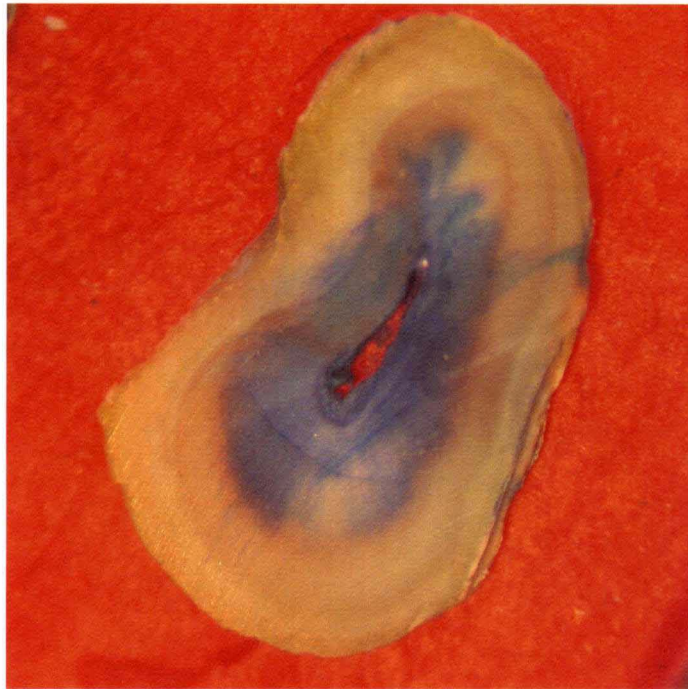
**FIGURE 84**

Microscopic view of tooth #21



**FIGURE 85**

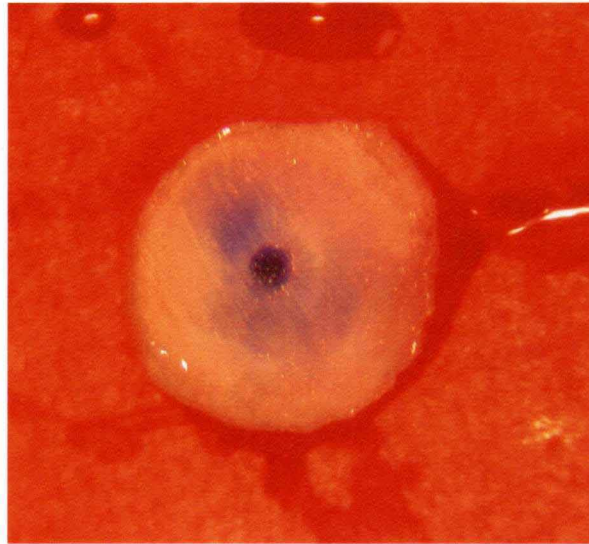
Microscopic view of tooth #22



**FIGURE 86**

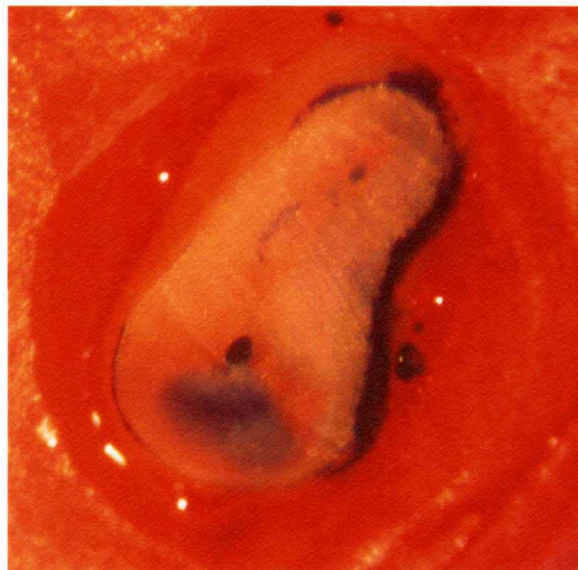Microscopic view of tooth #23





**FIGURE 87**

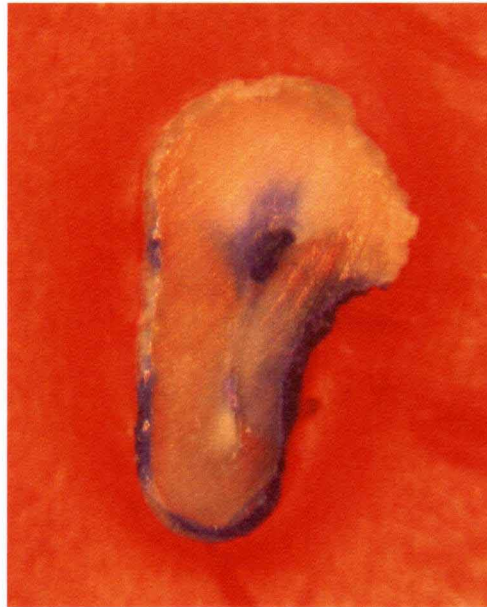
Microscopic view of tooth #24



**FIGURE 88**

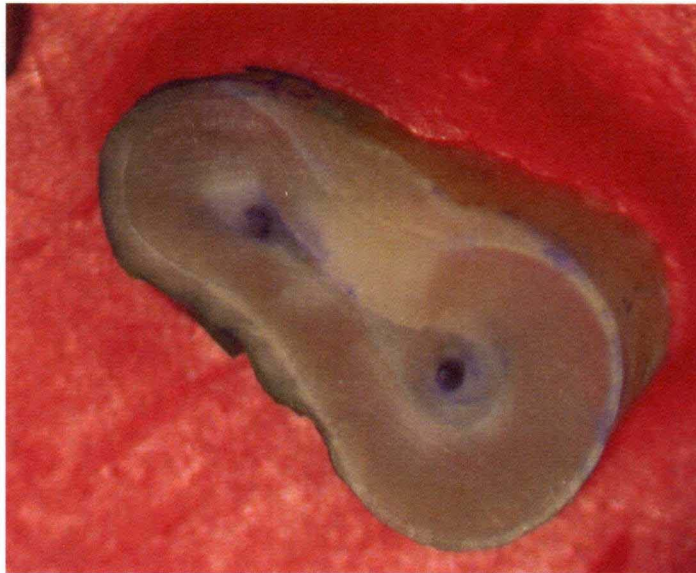Microscopic view of tooth #25





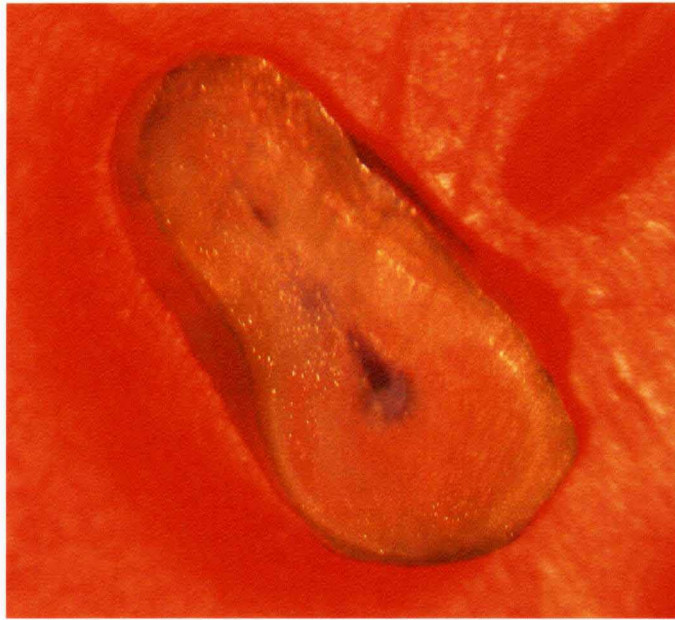**FIGURE 89**

Microscopic view of tooth #26



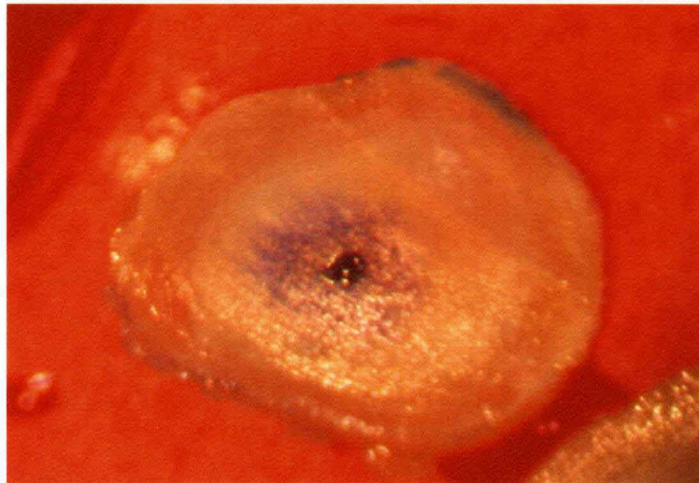
**FIGURE 90**

Microscopic view of tooth #27



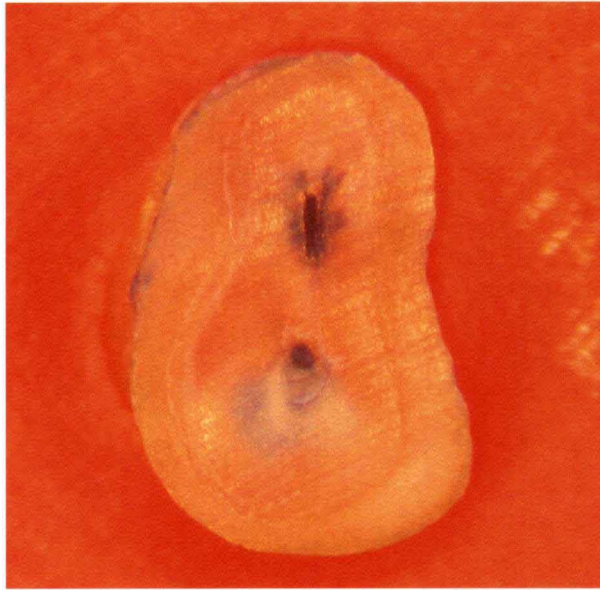**FIGURE 91**

Microscopic view of tooth #28



**FIGURE 92**

Microscopic view of tooth #29



**FIGURE 93**

Microscopic view of tooth #30



**FIGURE 94**

Microscopic view of tooth #31

## **Data Analysis**

Agreement between eight different raters' choice and the ground truth for the three resolutions was calculated and presented. Three groups of raters (endodontic faculty, second year residents and first year residents) were compared to see if there was any difference in rater accuracy with the weighted Chi Square test for Independence. The *a priori* level of significance was set at  $p \leq 0.05$ . Intraclass Correlation Coefficient (ICC) was used to compare inter-rater and intra-rater reliability. The ICC was used to assess the consistency of measurements made by multiple observers measuring the same quantity.

## CHAPTER IV

### RESULTS

#### Ground Truth

Table (2) below shows the status of the 31 molars in the sample. Twenty four (24) of the 31 (77.4%) maxillary molars had two MB canals upon careful analysis of 2 mm horizontal cross-sections and seven teeth (7) (22.6%) maxillary molars had one MB canal.

**TABLE 2**

Ground Truth

<b>TOOTH NUMBER</b>	<b>GROUND TRUTH</b>
TOOTH #1	<b>One Canal</b>
TOOTH #2	Two Canals
TOOTH #3	Two Canals
TOOTH #4	Two Canals
TOOTH #5	Two Canals
TOOTH #6	Two Canals
TOOTH #7	Two Canals
TOOTH #8	Two Canals
TOOTH #9	<b>One Canal</b>
TOOTH #10	<b>One Canal</b>

TOOTH #11	Two Canals
TOOTH #12	Two Canals
TOOTH #13	Two Canals
TOOTH #14	Two Canals
TOOTH #15	Two Canals
TOOTH #16	Two Canals
TOOTH #17	Two Canals
TOOTH #18	Two Canals
TOOTH #19	Two Canals
TOOTH #20	Two Canals
TOOTH #21	<b>One Canal</b>
TOOTH #22	Two Canals
TOOTH #23	<b>One Canal</b>
TOOTH #24	<b>One Canal</b>
TOOTH #25	Two Canals
TOOTH #26	Two Canals
TOOTH #27	Two Canals
TOOTH #28	Two Canals
TOOTH #29	<b>One Canal</b>
TOOTH #30	Two Canals
TOOTH #31	Two Canals



**Descriptive measure of overall accuracy of 744 original ratings:**

66.3% of total responses were correct.

33.7% of total responses were incorrect.

**CORRECT RESPONSES:**

19% raters answered one canal and the truth was 1.

47.2% raters answered two canals and the truth was 2.

**INCORRECT RESPONSES:**

29.2% raters answered one canal and the truth was 2.

4.6% raters answered two canals and the truth was 1.

**Descriptive measure of overall accuracy of 240 repeats ratings:**

66.6% of total responses were correct.

33.4% of total responses were incorrect.

**CORRECT RESPONSES:**

12.9% raters answered one canal and the truth was 1.

53.9% raters answered two canals and the truth was 2.

**INCORRECT RESPONSES:**

26.2% raters answered one canal and the truth was 2.

7% raters answered two canals and the truth was 1.

Truth	1 Canal	2 Canals	Total
Raters Choice 1 Canal	142-31	217-63	359-94
Rater's Choice 2 Canals	34-17	351-129	385-146
Total	176-48	568-192	744-240

Original Videos

Repeat Videos

## Rater Choice Compared to Truth

FIGURE 95

### Descriptive measure of overall accuracy for both original and repeat ratings:

66.3% of total responses were correct.

33.7% of total responses were incorrect.

#### CORRECT RESPONSES:

17.6% raters answered one canal and the truth was 1.

48.7% raters answered two canals and the truth was 2.

#### INCORRECT RESPONSES:

28.5% raters answered one canal and the truth was 2.

5.2% raters answered two canals and the truth was 1.

Truth	1 Canal	2 Canals	Total
Raters Choice 1 Canal	173	280	453
Rater's Choice 2 Canals	51	480	531
Total	224	760	984

**Rater Choice Compared to Truth  
in both original and repeat videos**

**FIGURE 96**

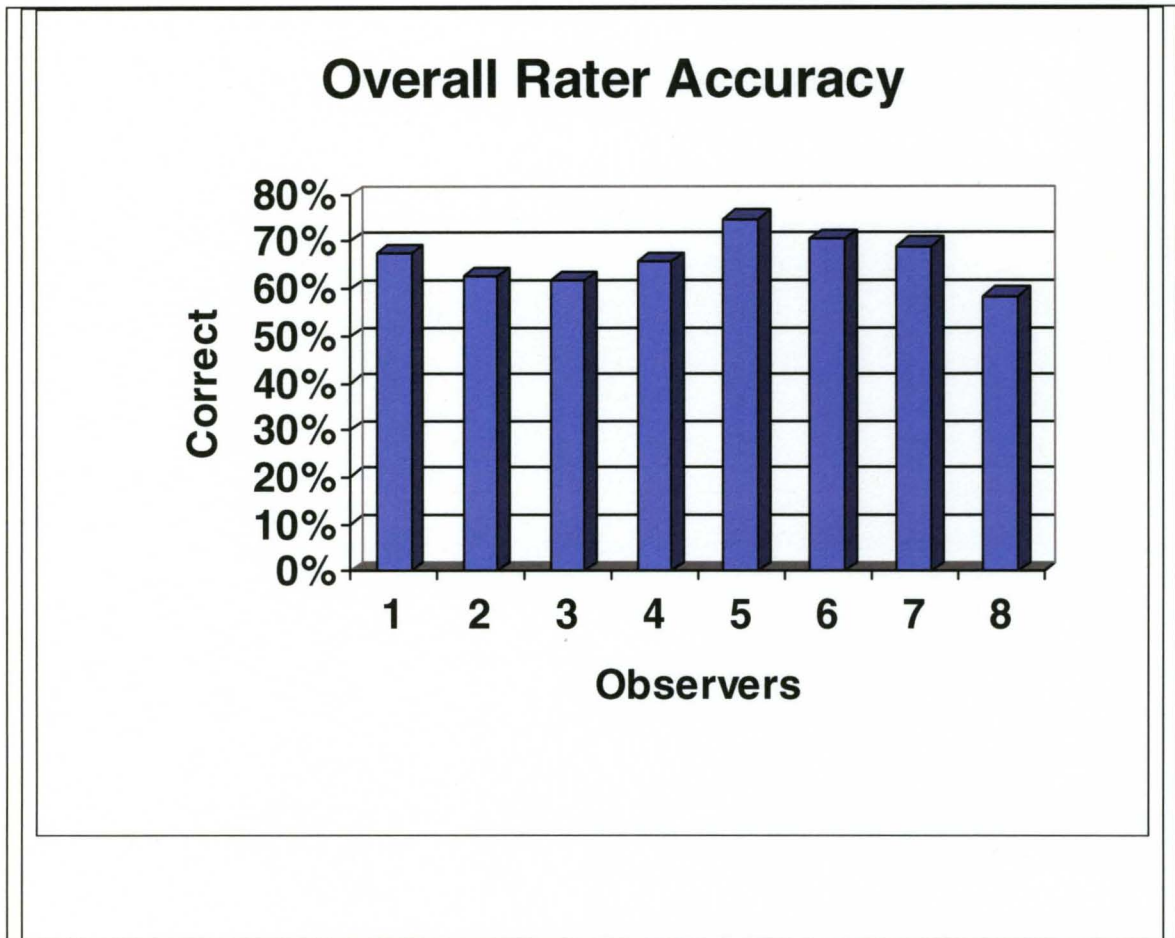
**Overall Rater Accuracy**

The percentages of overall correct responses compared to the truth for each observer is as follows: Observer 1 (endodontic faculty (ef)): 67.5%, Observer 2 (endodontic faculty (ef)): 62.6%, Observer 3 (endodontic faculty (ef)): 61.8% , Observer 4 (second year resident (2yr)): 65.9%, Observer 5 (second year resident (2yr)): 74.8%, Observer 6 (first year resident (1yr)): 70.7%, Observer 7 (first year resident (1yr)):69.1%, Observer 8 (first year resident (1yr)): 58.5% (table 3)

**TABLE 3**  
**Rater Accuracy with Observers Experience**

TABLE Rater Accuracy with Observers Experience		
Observer	Experience	Accuracy
1	ef	67.5%
2	ef	62.6%
3	ef	61.8%
4	2yr	65.9%
5	2yr	74.8%
6	1yr	70.7%
7	1yr	69.1%
8	1yr	58.5%

ef- endodontic faculty, 1yr – first year resident, 2yr- second year resident



**FIGURE 97**

Overall rater accuracy compared to the ground truth

**Overall Rater Accuracy Related to Experience and Resolution**

Detection rates of mesio-buccal canal in maxillary teeth were broken down into three different groups dependable on experience level and on resolution. I had three groups based on experience level: 1- endodontic faculty (three number of observers), 2- second year residents (two number of observers) and 3- first year endodontic residents (three numbers of observers). The resolutions were: 1- 0.076 voxel, 2- 0.1 voxel and 3- 0.2 voxel. In my study the second year residents had the best detection rate at 74.2% at 0.1



voxel resolutions and the worse detection rate had first year residents at 61.3% at 0.2 voxel resolutions. For comparison of the effect of experience on MB canal detection the raters were combined into their respective groups. The three groupings were compared to see if there was any difference in rater accuracy with a Chi-Square test for Independence.

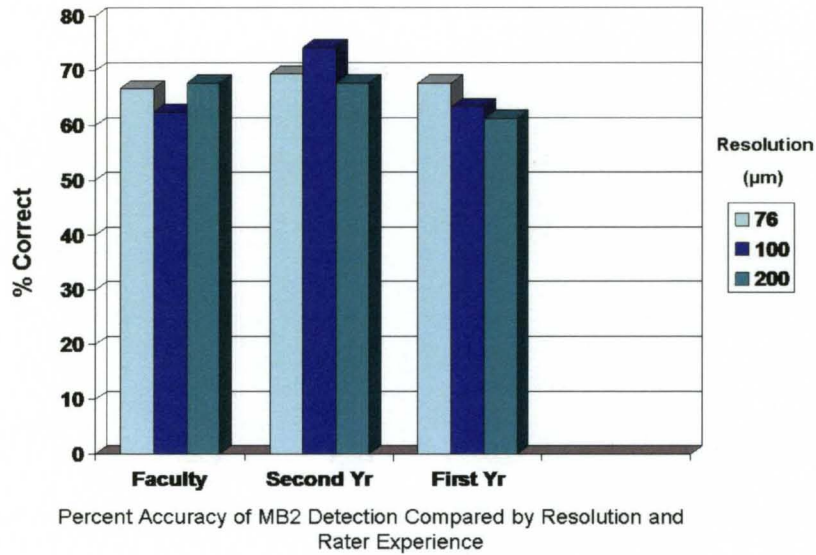
Measuring three groups of raters between correct choice at 0.076 voxel p value = 0.9549

Measuring three groups of raters between correct choice at 0.1 voxel p value = 0.2849

Measuring three groups of raters between correct choice at 0.2 voxel p value = 0.6095

The results indicated that there is NO statistically significant difference between detection of two canals in mesio-buccal root of maxillary molars between three different levels of experience.

These results are limited by the fact that there was a small sample size with only 2 – 3 raters in each group which could affect the results. Years of experience did not improve MB canal detection with CBCT as the endodontic faculty did not detect MB at a higher rate than the residents with less experience.



**FIGURE 98**

Following a two week gap in time, the Kodak 9000 3D images were again viewed in randomized order independently by the same observers, but this time using the native software provided by Practiceworks for viewing Kodak 9000 3D images

**Accuracy using the Kodak 9000 3D native imaging software:**

	0.076 mm	0.100 mm	0.200 mm
Correct	181	179	182
Incorrect	67	69	66

Total readings = 744 (correct = 542; incorrect = 202)

$p = 0.967$  (X2 test for independence)

*i.e.* no significance was proven related to isotropic voxel resolution using the Kodak 9000 3D system for the task of accurately determining the number of mesio-buccal canals in maxillary molar teeth. Images at high resolution did appear clearer but this did not prove

to alter diagnostic outcomes. For teeth with one mesio-buccal canal overall accuracy was 66.7%. For teeth with two mesio-buccal canals overall accuracy was 74.7%.

Comparing raters the respective (%) correct answers were 77%, 73%, 73%, 74%, 61%, 72%, 73%, and 78%.  $p = 0.266$  (X2 test for independence).

## **CHAPTER V**

### **DISCUSSION AND CONCLUSION**

#### **Discussion:**

Conventional 2D digital intraoral radiography provides clinicians with an accessible, cost effective, high resolution imaging modality that continues to be of value in endodontic therapy. There are, however, specific situations, both pre- and post-operatively, where the understanding of spatial relationships afforded by CBCT facilitates diagnosis and influences treatment. Previous studies have shown that the likelihood of accurate detection of the correct number of root canals in the mesio-buccal root of the maxillary molar is little better than a coin toss when using conventional 2D images. CBCT even at 0.4 mm isotropic voxel resolution outperformed the previous studies at the University of Louisville using 2D film, solid state and photostimulable phosphor imaging, and with Tuned Aperture Computed Tomography (53-55).

This new study using the Kodak 9000 again confirms that CBCT provides greater accuracy than 2D dental imaging and the use of Tuned Aperture Computed Tomography; however, it failed to produce the high levels of accuracy attained with the i-CAT native images captured at the isotropic voxel resolution setting of 0.12 mm. Indeed, the results in the present study were similar to those obtained with 0.3-0.4 mm isotropic voxel resolution in the previous study by Baughman (56).

There was in any event an improved accuracy yield with this study using 3D imaging in comparison with the prior studies using 2D radiography and limited basis image information from Tuned Aperture Computed Tomography. Baughman previously determined detection of such canals was substantially spatial resolution related. In his study, to obtain a reliability of accurate interpretation of the number of mesio-buccal canals in maxillary molars above 90% required an isotropic voxel resolution approaching 0.1 mm, whereas at 0.4 mm the accuracy was only 60.1%. It was therefore recommended that where 3D imaging is desired for endodontic assessment, CBCT systems capable of high resolution should be employed. The influence of number of basis images to reduce image noise needs to also be considered. Using the i-CAT the higher resolution images also used twice the number of basis images as were used in the lower resolution scans. To minimize the radiation dose to the patient it is further recommended that systems permitting collimation to a narrow field of view be utilized. A joint effort is presently in progress between the American Academy of Oral and Maxillofacial Radiology and the American Association of Endodontists to establish guidelines for use of CBCT for Endodontics (57). Once no diagnostic difference was proven in image accuracy between the different resolutions AVIs from the Anatomage software for observer convenience we returned to the native Kodak software to re-read the images.

Following a two week gap in time, the Kodak 9000 3D images were again viewed in randomized order independently by the same observers, but this time using the native software provided by Practiceworks for viewing Kodak 9000 3D images.



## **Conclusion:**

3D imaging using CBCT is beneficial to assist in determination of the number of canals in the mesio-buccal root of maxillary molars. It is likely to also be of use for detection of root fractures with minimal separation, and in other subtle tasks that defy the cause of endodontically-related symptoms or failed endodontic treatments.

- (1) Using the i-CAT CBCT system there was a significant positive relationship between isotropic voxel resolution and accuracy in detection of mesio-buccal canals in maxillary molars, with higher resolution meaning greater performance. At 0.125 mm isotropic voxel resolution accuracy exceeded 93%, whereas as at 0.4 mm isotropic voxel resolution the accuracy was 60%. No statistical differences were proven for a resolution greater than 0.200 mm.
- (2) Using the Kodak 9000 3D, while image quality was subjectively better with improved voxel resolution, no diagnostic difference was proven either for the native Kodak imaging software or for the same images exported to Anatomage *InVivoDental*. We originally used the AVIs from the Anatomage software for observer convenience, but returned to the native Kodak software once no difference was proven in image diagnostic accuracy between the different resolutions. For teeth with one mesio-buccal canal overall accuracy was 66.7%. For teeth with two mesio-buccal canals overall accuracy was 74.7%. Exporting into Anatomage *InVivoDental* had no detriment on the diagnostic value of the Kodak 9000 3D images.

- (3) Comparing the two systems the findings with the Kodak 9000 3D system at 0.076-0.200 mm isotropic voxel resolution proved accuracy at this range to be equivalent to the i-CAT images using a 0.300 mm isotropic voxel resolution.
- (4) It can be concluded that isotropic voxel resolution is important when using the i-CAT CBCT system for high definition tasks, but that this is not the case for the Kodak 9000 3D system. There are obviously additional factors in the imaging chain other than voxel resolution that may affect diagnostic image quality. For instance, there is a trade off between patient dose and the resulting signal to noise ratio. When dose is reduced to a very low level, as is the case with the Kodak 9000 3D, the potential untoward effects of radiation on the patient are constrained. Perhaps in striving to minimize dose, there is a loss of contrast that could impede high resolution tasks despite the Kodak 9000 3D having the smallest voxel resolution available at the time of this study.

**Caveats:**

- (1) This study was conducted *in vitro*. Clinical trials are required to establish whether the same outcomes would be achieved *in vivo*.
- (2) This study investigated just one diagnostic task out of the very many different applications for CBCT. The task chosen was one that requires greater contrast and spatial resolution than is the case for most other diagnostic needs in dentistry. The results of this study should not be extrapolated to applications beyond the scope of the investigational parameters utilized. Statistical differences in accuracy were not found for resolutions > 0.200 mm for either system.

## REFERENCES

1. Bender IB, Seltzer S. Roentgenographic and direct observation of experimental lesions in bone: I. *J Am Dent Assoc.* 1961;62:152-160.
2. Bender IB, Seltzer S. Roentgenographic and direct observation of experimental lesions in bone: I. *J Am Dent Assoc.* 1961;62:708-716.
3. van der Stelt PF. Experimentally produced bone lesions. *Oral Surg Oral Med Oral Pathol.* 1985;59(3):306-312.
4. White SC, Atchinson KA, Hewlett ER, et al. Efficacy of FDA guidelines for prescribing radiographs to detect dental and intraosseous conditions. *Oral Surg Oral Med Oral Pathol Oral Radiol Endod.* 1995;80(1):108-114.
5. Suomalainen AK, Salo A, Robinson S, et al. The 3DX multi image micro-CT device in clinical dental practice. *Dentomaxillofac Radiol.* 2007;36(2):80-85.
6. Estreala C, Bueno MR, Leles CR, et al. Accuracy of cone beam computed tomography and panoramic and periapical radiography for detection of apical periodontitis. *J Endod.* 2008;34(3):273-279.
7. Anonymous. From Nobel Lectures. Physics 1901-1921, cited 1967; Available from: [http://nobelprize.org/nobel\\_prizes/physics/laureates/1901/rontgen-bio.html](http://nobelprize.org/nobel_prizes/physics/laureates/1901/rontgen-bio.html)
8. Arnheiter C, Scarfe WC, Farman AG. Trends in maxillofacial cone-beam computed tomography usage. *Oral Radiol* 2006;22:80-85.
9. Gelbier S. 125 years of developments in dentistry, 1880-2005 Part 3: Dental equipment and materials. *British Dental Journal* 2005;199:536-539.
10. Truong TT, Nguyen MK, Zaidi H. The Mathematical Foundations of 3D Compton Scatter Emission Imaging. *International journal of biomedical imaging* 2007;2007:92780.
11. Cormack A, M. Early two-dimensional reconstruction (CT scanning) and recent topics stemming from it. Nobel lecture, December 8, 1979. *J Comput Assist Tomogr* 1980; 4:658-664.
12. Hounsfield GN. Nobel lecture, 8 December 1979. Computed medical imaging. *J Radiol* 1980; 61(6-7):459-468.

13. Patel S, Dawood A, Ford TP, Whaites E. The potential applications of cone beam computed tomography in the management of endodontic problems. *International endodontic journal* 2007;40(10):818-830.
14. Sukovic P. Cone beam computed tomography in maxillofacial imaging. *Orthod Craniofac Res.* 2003; 6(Suppl 1):31-36.
15. Robb RA. Dynamic Spatial Reconstruction: An X-ray Video Fluoroscopic CT scanner for dynamic volume imaging of moving organs. *IEEE Trans Med Imag*, 1982. MI-1(1): pp.22-23.
16. Saint-Felix D, Troussset Y, Picard C, Ponchut C, Roméas R, Rougée A. In vivo evaluation of a new system for 3D computerized angiography. *Phys Med Biol* 1994; 39:583-595.
17. Rougée A, Picard C, Saint-Félix D, Troussset Y, Moll T, Amiel M. Three dimensional coronary arteriography. *Int J Card Imaging* 1994; 10:67-70.
18. Fahrig R., Fox AJ, Lownie S, Holdsworth DW. Use of a C-arm system to generate true three-dimensional computed rotational angiograms: preliminary in vitro and in vivo results. *AJNR Am J Neuroradiol* 1997;18:1507-1514.
19. Schueler BA, Sen A, Hsiung HH, Latchaw RE, Hu X. Three-dimensional vascular reconstruction with a clinical X-ray angiography system. *Acad Radiol* 1997; 4: 693-699.
20. Kawata Y, Niki N, Kumazaki T. Measurement of blood vessel characteristics for disease detection based on cone beam CT images. *IEEE Trans Med Imaging* 1996; 43:3348-3354.
21. Ning R, Chen B, Yu R, Conover D, Tang X, Ning Y. Flat panel detector-based cone-beam volume CT angiography imaging: system evaluation. *IEEE Trans Med Imaging* 2000; 19: 949-963.
22. Cho PS, Johnson RH, Griffin TW. Cone-beam CT for radiotherapy applications. *Phys Med Biol* 1995; 40:1863-1883.
23. Petit SF, van Elmpt WJ, Nijsten SM, Lambin P, Dekker AL. Calibration of megavoltage cone-beam CT for radiotherapy dose calculations: correction of cupping artifacts and conversion of CT numbers to electron density. 2008; 35:849-865.
24. Li H, Zhu XR, Zhang L, Dong L, Tung S, Ahamad A, Chao KS, Morrison WH, Rosenthal DI, Schwartz DL, Mohan R, Garden AS. Comparison of 2D radiographic images and 3D cone beam computed tomography for positioning head-and-neck radiotherapy patients. *Int J Radiat Oncol Biol Phys* 2008; 71:916-

925.

25. Marchant TE, Amer AM, Moore CJ. Measurement of inter and intra fraction organ motion in radiotherapy using cone beam CT projection images. *Phys Med Biol* 2008; 21; 53:1087-1098.
26. Ning R, Chen B, Yu R, Conover D, Tang X, Ning Y. Flat panel detector-based cone-beam volume CT angiography imaging: system evaluation. *IEEE Trans Med Imaging* 2000; 19: 949-963.
27. Karellas A, Lo JY, Orton CG. Point/Counterpoint. Cone beam x-ray CT will be superior to digital x-ray tomosynthesis in imaging the breast and delineating cancer. *Med Phys* 2008; 35:409-411.
28. Farman AG, Levato CM, Scarfe WC. A primer on cone beam computed tomography. *Inside Dentistry*. 2007; 3(Jan):90-92.
29. Farman AG, Levato CM, Scarfe WC. 3D X-ray: An update. *Inside Dentistry*. 2007; 3(Jun):70-74.
30. Farman AG, Levato CM, Scarfe WC, Mah J. Education in the round: multidimensional imaging in dentistry. *Inside Dentistry* 2008;(Jan):39-41.
31. Walton R. E. , "Diagnostic imaging A. endodontic radiography," in *Ingles' Endodontics*, J. I. Ingle, L. K. Bakland, and J. C. Baumgartner, Eds., p. 554, BC Decker, Hamilton, Canada, 6th edition, 2008.
32. Scarfe WC, Levin MD, Gane D, Farman AG. Use of Cone Beam Computed Tomography in Endodontics. *Int J Dent* 2009 (2009), Article ID 634567, 20 pages doi:10.1155/2009/634567.  
<http://www.hindawi.com/journals/ijd/2009/634567.html> accessed April 2, 2010.
33. Rushton V.E, K. Horner, and H. V. Worthington, "Screening panoramic radiology of adults in general dental practice: radiological findings," *Brit Dent J* 2001;190:495-501.
34. Healey, H. J.: *Endodontics*, St. Louis, 1960, The C. V. Mosby Company.
35. Ingle, J. I: *Endodontics*, Philadelphia, 1965, Lea & Febiger.
36. Weine FS, Healey HJ, Gerstein H, Evanson L.: Canal configuration in the mesibuccal root of the maxillary first molar and its endodontic significance. *Oral Surg Oral Med Oral Pathol* 28 (3), 1969.
37. Weine FS, Healey HJ, Gerstein H, Evanson L.: Incremental Instrumentation and Pre-Curving of Files as Aids in Canal Preparation. Unpublished data.




38. Seidberg BH, Altman M, Guttuso J, Suson M: Frequency of two mesio-buccal root canals in maxillary permanent first molars. *JADA* 87:825-856, 1973.
39. Vigouroux SAC, Bosaans SAT: Anatomy of the pulp chamber floor of the permanent maxillary first molar. *J Endod* 4(7):214-219, 1978.
40. Gilles J, Reader A: An SEM investigation of the mesiolingual canal in human maxillary first and second molars. *Oral Surg Oral Med Oral Pathol* 70(5):638-643, 1990.
41. Kulild JC, Peters DD: Incidence and configuration of canal systems in the mesio-buccal root of maxillary first and second molars. *J Endod* 16(7):311-317, 1990.
42. Fogel HM, Peikoff MD, Christie WH: Canal configuration in the mesio-buccal root of the maxillary first molar: A clinical study. *J Endod* 20(3):135-137, 1994.
43. Hartwell G, Bellizi R. Clinical investigation of in vivo endodontically treated mandibular and maxillary molars. *J Endodon* 1982;8:555-7.
44. Corcoran J, Apicella MJ, Mines P: The effect of operator experience in locating additional canals in maxillary molars. *J Endod* 33(1):15-17, 2007.
45. Wolcott J, Ishley D, Kennedy W, Johnson S, Minnich S: Clinical investigation of second mesio-buccal canals in endodontically treated and retreated maxillary molars. *J Endod* 28(6):477-479, 2002.
46. Vertucci FJ: Root canal morphology and its relationship to endodontic procedures. *Endodontic Topics* 10:3-29, 2005.
47. Walton RE. Endodontic radiographic techniques. *Dental radiography and photography* 1973;46(3):51-59.
48. Martinez-Lozano MA, Forner-Navarro L, Sanchez-Cortes JL. Analysis of radiologic factors in determining premolar root canal systems. *Oral surgery, oral medicine, oral pathology, oral radiology, and endodontics* 1999;88(6):719-722.
49. Weine FS, Healey HJ, Gerstein H, Evanson L. Canal configuration in the mesio-buccal root of the maxillary first molar and its endodontic significance. *Oral surgery, oral medicine, and oral pathology* 1969;28(3):419-425.
50. Goerig AC, Neaverth EJ. A simplified look at the buccal object rule in endodontics. *JOE* 1987;13(12):570-572.
51. Filho FB, Zaitter S, Haragushiku GA, de Campos EA, Abuabara A, Correr GM: Analysis of the internal anatomy of maxillary first molars by using different methods. *J Endod* 35(3):337-342, 2009.

52. Somma F, Leoni D, Plotino G, Grande NM, Plasschaert A: Root canal morphology of the mesio-buccal root of maxillary first molars: a micro-computed tomographic analysis. *Int Endod J* 42:165-174, 2009.
53. Ramamurthy R, Scheetz JP, Clark SJ, Farman AG. Effects of imaging system and exposure on accurate detection of the second mesio-buccal canal in maxillary molar teeth. *Oral Surg Oral Med Oral Pathol Oral Radiol Endod* 2006;102:796-802.
54. Barton DJ, Clark SJ, Eleazer PD, Scheetz JP, Farman AG. Tuned Aperture Computed Tomography (TACT) versus parallax analog and digital radiographic images in detecting second mesio-buccal canals in maxillary first molars. *Oral Surg Oral Med Oral Pathol Oral Radiol Endod* 2003;96:223-228.
55. Farman , Sauer J, Bauman R, Clark S, Scarfe W. Digital imaging and detection rates for accurate depiction maxillary molar root canals: CBCT considerations. *Int J Comput Assist Radiol Surg* 2010: In press.
56. Baughman R, In Vitro detection of mesiobuccal canals in maxillary molar cross-sections using four different isotropic voxel dimentions, Master Thesis, Unpublished.
57. Farman AG. Personal communication from the President of the American Academy of Oral and Maxillofacial Radiology.

## APPENDIX A

### Approval of Protocol by Human Studies Committee



**UNIVERSITY of LOUISVILLE**

**INSTITUTIONAL REVIEW BOARDS**

University of Louisville  
MedCenter One, Suite 200  
501 E. Broadway  
Louisville, Kentucky 40202-1796  
Office: 502-852-5188  
Fax: 502-852-2164

**Expedited - Case Report / NHSR - Acknowledgement**

**To:** Clark, Stephen  
**From:** Human Subjects Protection Program Office  
**Date:** Wednesday, April 30, 2008  
**Subject:** No action required


**Tracking #:** CASE-37  
**Title:** Use of Extracted Teeth For Bench-top Research in School of Dentistry

---

I have reviewed your submission and the case report described does not meet the "Common Rule" definition of human subjects' research. Therefore, this report does not require IRB review prior to completing the work.


If you have any questions please contact the HSPPO office at (502) 852-5188.

Thank you.



Board Designee: Walker, Frank  
Letter Sent By: Dearinger, Barbara, 4/30/2008 2:08 PM

Full Accreditation since June 2005 by the Association for the Accreditation of Human Research Protection Programs, Inc.



## APPENDIX B

### Random Sequence Generator for 123 numbers

83	22	89
63	94	114
33	115	84
118	99	123
74	40	1
30	76	9
110	108	101
38	80	102
55	64	45
41	54	96
77	120	49
105	71	106
47	19	18
73	112	90
20	16	78
50	23	39
67	107	26
12	2	104
8	37	81
52	46	93
15	103	21
35	56	59
3	98	57
119	6	44
86	85	92
53	121	5
60	62	28
11	68	48
116	91	100
97	58	69
109	4	79
43	27	34
36	13	72
65	82	7
24	31	17
29	42	25
87	75	51
117	14	10
61	113	66
32	88	
111	95	
122	70	

## APPENDIX C

### Random Video Order Numbers with repeats

Video Order	Tooth #	Resolution	Repeat	Sequence #
1	21	200	No	83
2	1	200	No	63
3	2	100	No	33
4	27	200	Yes	118
5	12	200	No	74
6	30	76	No	30
7	16	100	Yes	110
8	7	100	No	38
9	24	100	No	55
10	10	100	No	41
11	15	200	No	77
12	14	100	Yes	105
13	16	100	No	47
14	10	200	No	73
15	20	76	No	20
16	18	100	No	50
17	5	200	No	67
18	12	76	No	12
19	8	76	No	8
20	21	100	No	52
21	15	76	No	15
22	4	100	No	35
23	3	76	No	3
24	4	200	Yes	119
25	24	200	No	86
26	22	100	No	53
27	29	100	No	60
28	11	76	No	11
29	5	200	Yes	116
30	23	76	Yes	97
31	26	100	Yes	109
32	12	100	No	43
33	5	100	No	36
34	3	200	No	65
35	24	76	No	24
36	29	76	No	29
37	25	200	No	87
38	2	200	Yes	117
39	30	100	No	61
40	1	100	No	32

41	2	100	Yes	111
42	25	200	Yes	122
43	22	76	No	22
44	16	76	Yes	94
45	6	200	Yes	115
46	28	76	Yes	99
47	9	100	No	40
48	14	299	No	76
49	20	100	Yes	108
50	19	200	No	80
51	2	200	No	64
52	22	100	No	54
53	19	200	Yes	120
54	9	200	No	71
55	19	76	No	19
56	12	100	Yes	112
57	16	76	No	16
58	23	76	No	23
59	19	100	Yes	107
60	2	76	No	2
61	6	100	No	37
62	15	100	No	46
63	20	76	Yes	103
64	26	100	No	56
65	14	76	Yes	98
66	6	76	No	6
67	23	200	No	85
68	29	200	Yes	121
69	31	100	No	62
70	6	200	No	68
71	29	200	No	91
72	27	100	No	58
73	4	76	No	4
74	27	76	No	27
75	13	76	No	13
76	22	200	No	82
77	31	76	No	31
78	10	100	No	42
79	13	200	No	75
80	14	76	No	14
81	24	100	Yes	113
82	27	200	No	88
83	24	76	Yes	95
84	8	200	No	70
85	28	200	No	89
86	15	200	Yes	114
87	22	200	No	84
88	23	200	Yes	123



89	1	76	No	1
90	9	76	No	9
91	15	76	Yes	101
92	27	76	Yes	102
93	14	100	No	45
94	26	76	Yes	96
95	18	100	No	49
96	11	100	Yes	106
97	18	76	No	18
98	28	200	No	90
99	16	200	No	78
100	8	100	No	39
101	19	76	No	26
102	30	100	Yes	104
103	19	200	No	81
104	31	200	No	93
105	21	76	No	21
106	28	100	No	59
107	26	100	No	57
108	13	100	No	44
109	30	200	No	92
110	5	76	No	5
111	28	76	No	28
112	17	100	No	48
113	29	76	Yes	100
114	7	200	No	69
115	17	200	No	79
116	3	100	No	34
117	10	200	No	72
118	7	76	No	7
119	17	76	No	17
120	25	76	No	25
121	20	100	No	51
122	10	76	No	10
123	4	200	No	66

## APPENDIX D

### Written instructions given to observers

#### INSTRUCTIONS TO THE OBSERVERS

You will be watching a series of 123 videos. These videos will show a CT scan cross section of a tooth. In some cases when the video starts you will be looking at the crown of the tooth at the level of the CEJ. Some of them from the crown down. When the video starts the image will scroll down through the cross sections of the tooth root. It will take 15 – 20 seconds to scroll down each root. You can look at the video more than once if you have to but watch carefully.

All teeth are maxillary first or second molars. They are arranged so that the palatal aspect of the tooth will be toward the top of the screen. There are both maxillary right and left molars. It is up to you to determine which root is the MB root during the video and evaluate for the presence of MB2

You will rate the presence of MB2 using a two point confidence scale. Place an X in the box marked 1 or 2 according to the following criteria:

- 1 One mesio buccal canal detected,  
One oblong canal or  
One canal with a fin but no second canal at the end of the fin  
Unable to detect a canal at all
- 2 Two or more mesio-buccal canals detected

If a second MB canal can be visualized at any cross section it is considered to be present. An answer of 2 does not mean you can see a second canal through the whole root, but that you can visualize it at any point during the video.

Thank you for your time!

## APPENDIX E

Observers' assessment form

### OBSERVERS ASSESSMENT FORM

<b>Video Number</b>	<b>1 - canal</b>	<b>2 - canals</b>
-------------------------	------------------	-------------------

1		
2		
3		
4		
5		
6		
7		
8		
9		
10		
11		
12		
13		
14		
15		
16		
17		
18		
19		
20		
21		
22		
23		
24		
25		
26		
27		

28		
29		
30		
31		
32		
33		
34		
35		
36		
37		
38		
39		
40		
41		
42		
43		
44		
45		
46		
47		
48		
49		
50		
51		
52		
53		
54		
55		
56		
57		
58		
59		
60		
61		
62		
63		
64		
65		
66		
67		

68		
69		
70		
71		
72		
73		
74		
75		
76		
77		
78		
79		
80		
81		
82		
83		
84		
85		
86		
87		
88		
89		
90		
91		
92		
93		
94		
95		
96		
97		
98		
99		
100		
101		
102		
103		
104		
105		
106		
107		
108		
109		
110		
111		

112		
113		
114		
115		
116		
117		
118		
119		
120		
121		
122		
123		

- 1 = One mesio buccal canal detected,  
One oblong canal or  
One canal with a fin but no second canal at the end of the fin  
Unable to detect a canal at all
- 2 = Two or more mesio-buccal canals detected



## CURRICULUM VITAE

*JOLANTA N. SAUER*

---

### *EDUCATION*

---

- As of July 1, 2008, full-time resident in the endodontic specialty program at the University of Louisville School of Dentistry. Expected completion date – June 2010.
- DMD: University of Louisville School of Dentistry – May 2005.
- MS in Oral Biology: University of Louisville School of Dentistry – nearing completion.
- DMD: Medical University, Wroclaw, Poland – June 1998.
- BS Degree (Biochemistry): IV Liceum Ogolnoksztalce Im.Hanki Sawickiej in Kielce, Poland – 1993.

### *PROFESSIONAL EXPERIENCE*

---

- July 2007 – June 2008      Faculty Practice, University of Louisville School of Dentistry, Louisville, Kentucky
- July 2006 – June 2008      Clinical Assistant Professor, University of Louisville School of Dentistry, Louisville, Kentucky
- July 2005 – June 2006      General Residency Program, University of Louisville, Ambulatory Care Building, Louisville, Kentucky
- May 2005 – July 2005      Part time clinical faculty - Emergency Clinic, University of Louisville School of Dentistry
- Sept 2002 – May 2005      Student Researcher – The University of Louisville School of Dentistry and Hazelwood Clinic

## *SERVICE AND SCHOOL ACTIVITIES*

---

- July 2007 – June 2008 Junior Group Manager, University of Louisville School of Dentistry, Louisville, Kentucky
- July 2007 – June 2008 Clinic Operations and Patient Committee (COPC)
- May 19 – 20 and June 23 - 24, 2007 Course Instructor for Continuing Education Course: EDDA: The Restorative Expanded Duty Dental Assistant
- Spring Semester 2007 Clinical Course Instruction for Sophomore Complete Denture Course
- February 7, 2007 Judge at the 32nd Annual Dental School Student Convention Research and Table Clinic Competition at Clarion Hotel
- February 2, 2007 Smile Kentucky Program at School of Dentistry
- January 20, 2007 Fixed Prosthodontics grader during Mock Board
- January 19, 2007 Floor Coordinator during Mock Board

## *PUBLICATIONS & PRESENTATIONS*

---

**“A BRIEF HISTORY OF MAXILLOFACIAL CONE BEAM COMPUTED TOMOGRAPHY WITH SPECIAL ATTENTION TO SAFETY CONSIDERATIONS,”** by Allan G. Farman, Jolanta Sauer, Lakshmi Garladinne-Nethi, Stephen Clark and William C. Scarfe, Published in *e-Dentico* 2/22/2009 the Polish and English Journal for Dentists.

**“GINGIVAL HYPERPLASIA RECURRENCE IN PATIENTS WITH MR/DD RETURNED TO DILANTIN”**

- *Selected to represent University of Louisville School of Dentistry at the annual IADR meeting in Baltimore, Maryland in March 2005*
- *Presented at Louisville Research, 2005*

**“OUTCOMES OF SUBSTITUTING ALTERNATIVE REGIMENS FOR DILANTIN IN PATIENTS WITH MR/DD”**

- *Selected to represent University of Louisville School of Dentistry at the annual IADR meeting in Honolulu, Hawaii in March 2004*
- *Selected to represent University of Louisville School of Dentistry at the annual ADA meeting in Orlando, Florida in October 2004*

- *Presented at 29th Annual Student Convention held in Clarion Hotel, Louisville, Kentucky in February 2004*
- *Presented at the KDA meeting, 2004*
- *Presented at Research Louisville, 2004*

**“SUBSTITUTION OF TOPOMAX ANTI-SEIZURE REGIMEN FOR DILANTIN IN MR/DD PATIENTS”**

- *Selected to represent University of Louisville School of Dentistry at the annual IADR meeting in San Antonio, Texas in March 2003*
- *Presented at Research Louisville, 2003*

*LEADERSHIP AND AWARDS*

---

- The Pierre Fauchard Academy Award for outstanding academic achievements in dentistry
- Quintessence Award in recognition of academic achievements
- The American Academy of Oral and Maxillofacial Radiology for greatest interest and accomplishment in Oral and Maxillofacial Radiology
- AADR National Student Research Group 2005 Caulk/Dentsply Competition Award for interest to and dedication to dental research
- ADA CREP for Continuing Education Recognition Program
- 2005 Palmolive Block Travel Grant Award for outstanding accomplishment in dental research
- 14th Annual Session ADA 2004 Orlando, Florida – contribution to the success of the Annual Session
- Second highest producer for the dental productivity at The University of Louisville School of Dentistry (updated 9/14/2005)
- President of The University of Louisville School of Dentistry Student Research Group
- Gross, Head and Neck Anatomy tutor
- Dean’s List
- 1st Place at KDA (Kentucky Dental Association) Research Competition
- Best Overall Poster Presentation at 29th Annual University of Louisville School of Dentistry Student Convention
- Representative of Advanced Radiology
- 2005 ADA/Dentsply Student Research Competition - 3rd Place in Louisville
- 2004 ADA/Dentsply Student Research Competition - 1st Place in Louisville
- 2003 ADA/Dentsply Student Research Competition - 2nd Place in Louisville